

Seizures and Syncope in the Cancer Patient

ALEXANDRA FLOWERS

Neurologic complications in cancer patients commonly involve altered levels of consciousness. This chapter discusses seizures and syncope, two problems in cancer patients that can have multiple causes. Whereas normally it is easy to distinguish between these two conditions, occasionally when there are no observers of the event, it can be difficult for the clinician to be certain whether a seizure or syncope has occurred. It is hoped that the sections that follow will help clarify the etiologies, presentations, and treatments for seizures and syncope in cancer patients, including those caused by drugs given for cancer therapy.

SEIZURES

Seizures are the first clinical manifestation in approximately 30% of patients with primary or metastatic brain tumors (Cascino, 1993; Stein and Chamberlain, 1991). In patients who have systemic cancer without brain metastases, the incidence of ictal phenomena is not well documented. In fact, there have been no prospective or retrospective studies of seizures in this group, and some seizures in these patients are not recognized as such (e.g., complex partial seizures). On occasion, non-ictal, abnormal movements may be confused with seizures.

Etiology

The etiology of seizures in cancer patients is presented in Table 20-1. More than one etiologic factor

may be present in a patient, so an accurate evaluation will require a comprehensive work-up of each patient.

Primary and Metastatic Brain Tumors

Primary and metastatic brain tumors can present with focal or generalized seizures. Among infiltrating gliomas, low-grade gliomas, particularly those involving the temporal lobe, are the most likely to cause seizures, usually with onset in childhood or in the teenage years (Bartolomei et al., 1997; Britton et al., 1994; Rogers et al., 1993). Patients with seizures caused by brain tumors present with generalized tonic-clonic seizures or simple or complex partial seizures, with or without secondary generalization. Unfortunately, at times the seizures are difficult to treat. Additionally, an increased frequency of seizures in a patient with a known low-grade brain tumor may indicate tumor transformation to a more malignant histology.

In general, patients with primary brain tumors who present with seizures but do not have magnetic resonance imaging (MRI) or computerized tomography (CT) confirmation of tumor at their initial evaluation have a better prognosis. This fact may reflect an earlier diagnosis of tumor and/or lower grade of malignancy. Improvement in MRI scanning techniques allows these patients to be diagnosed with tumor at an earlier time.

Surgery, when feasible, is a desired therapeutic approach for both tumor removal and seizure control (Britton et al., 1994). Modern techniques, such as brain mapping and intraoperative electroen-

Table 20–1. Etiology of Seizures in Cancer Patients

<i>Etiologic Factors</i>	<i>Causes</i>
Intracranial tumors	
Parenchymal	Primary tumors (gliomas), metastatic tumors
Meningeal	
Mass lesions	Primary tumors (meningiomas), metastatic tumors
Diffuse	Primary tumors (meningeal gliomatosis), metastatic tumors (meningeal carcinomatosis, lymphomatosis)
Systemic cancer	
Treatment-related	
Radiation therapy	Increased edema, radiation necrosis
Chemotherapy	Platinum, methotrexate, cytarabine, busulfan, l-asparaginase, 5-fluorouracil, ifosfamide, paclitaxel Intratumoral chemotherapy
Biologic agents	IL-2, interferon, lymphokine-activated killer cells, granulocyte-macrophage colony-stimulating factor
Other drugs	
Narcotics	Meperidine, morphine, propoxyphene
Neuroleptics	Haloperidol, phenothiazine
Antidepressants	Tricyclics, Prozac, Wellbutrin
Antibiotics	Betalactams, quinolones
IV contrast media	Radiologic contrast media used for CT scanning
Metabolic	
Hyponatremia	Volume depletion, overhydration, syndrome of inappropriate antidiuretic hormone secretion
Hypoglycemia	Malnutrition, pancreatic tumors, total parenteral nutrition withdrawal
Hypocalcemia	Nutritional, secondary to chemotherapy (cisplatin)
Hypomagnesemia	Drug-related (chemotherapy—cisplatin, amphotericin B), hypoparathyroidism
Hypoxia	Pulmonary fibrosis (chemotherapy related), pulmonary embolism, lung cancer (primary or metastatic)
Vascular	Stroke (thrombotic, embolic), vasculitis (paraneoplastic, treatment induced)
Hemorrhagic	
Parenchymal	Tumor, mycotic aneurysms, aspergillomas
Subdural	Post-traumatic, due to thrombocytopenia, after spinal taps
Subarachnoid	Spontaneous, due to thrombocytopenia or coagulopathy
Infectious	
Viral	Herpes simplex, herpes zoster, cytomegalovirus
Bacterial	Common pathogens, <i>Listeria</i> , <i>Mycobacterium</i>
Fungal	<i>Aspergillus</i> , <i>Cryptococcus</i>
Parasitic	Toxoplasmosis

cephalography, allow accurate identification of the seizure focus (Lim et al., 1991; Cascino, 1990; Smith et al., 1991). When surgical resection is not feasible, radiation therapy (RT) can help control the seizures (Rogers et al., 1993).

Systemic cancers most likely to metastasize to the brain are melanoma, lung carcinoma, renal cell carcinoma, breast carcinoma, cancers of the gastrointestinal tract, and choriocarcinoma (Trillet and Biron, 1989; Flowers and Levin, 1993; Rosner et al.,

1986). As time of survival increases with the use of chemotherapy, other types of cancer are thus given more time to develop and can also metastasize to the brain. Seizures can also occur secondary to parenchymal brain metastases and with dural and leptomeningeal metastases (Wasserstrom et al., 1982; Blaney et al., 1991).

Seizures Related to Paraneoplastic Syndromes

Although rare, paraneoplastic encephalomyeloneuritis can manifest with complex partial or generalized seizures, and these occur most frequently with anti-Hu-associated paraneoplastic encephalomyeloneuritis in patients with small cell lung carcinoma. Occasionally seizures occur in patients with paraneoplastic encephalomyeloneuritis associated with prostate or renal cell carcinoma (Dalmau et al., 1992; Drislane, 1994; Franck et al., 1987; de Toffol et al., 1997). Paraneoplastic temporal lobe epilepsy has even been reported in a patient with testicular cancer (Ahern et al., 1994).

Seizures Related to Radiation Therapy

The frequency of preexisting seizures may increase acutely during RT because of increased cerebral edema. With the use of corticosteroids to control edema and careful monitoring of antiepileptic drug levels, this is a rather infrequent occurrence. Seizures may also occur as a result of radiation-induced brain necrosis or vasculopathy, which are delayed effects of RT (Ciaudo-Lacroix and Lapresle, 1985; Rider, 1963; Spencer, 1998). Positron emission tomography and single-photon emission computed tomography scans of the brain can help to distinguish brain tumors from radiation-induced necrosis, although active epileptogenic foci caused by radiation necrosis can demonstrate hyperperfusion and hypermetabolism (Sasaki et al., 1996).

Seizures have been reported as immediate side effects (occurring within the first 2 weeks) in patients treated with radiosurgery. This may be due to a direct effect of irradiation on cellular permeability and leakage of irritative chemical products; no connection has been made with prior external beam radiation, use of corticosteroids, target volume, isodose, or pretreatment edema (Werner-Wasik et al., 1999).

Seizures Related to Chemotherapy

Seizures occur in fewer than 1% of patients treated with systemic chemotherapy and can occur as a manifestation of the neurotoxicity of chemotherapeutic agents. In general, chemotherapy-associated neurotoxicity is related to specific drugs or drug combinations, dose intensity, and route of administration (Weiss et al., 1974). Because the early studies predated both the CT and MRI era, it is possible that small cerebral tumor metastases were present in the patient population reported. The chemotherapeutic agents most commonly reported to cause central nervous system (CNS) toxicity are cisplatin, methotrexate, L-asparaginase, and busulfan. Neurotoxicity is also caused by high doses of busulfan, which is administered to recipients of bone marrow transplants (Antonini et al., 1998; Kramer et al., 1997; Snider et al., 1994; Tahsildar et al., 1996).

The frequency of neurologic toxic effects increases with intra-arterial or intrathecal administration, and blood-brain barrier modification and also when chemotherapy (especially methotrexate) is administered in conjunction with RT (Weiss et al., 1974; Feun et al., 1991; Stewart et al., 1992; Newelt and Dahlborg, 1987). Seizures have also been induced by fat emboli during the intra-arterial administration of cisplatin (Menendez et al., 1990).

Methotrexate. Moderate and high doses of intravenous methotrexate can cause leukoencephalopathy with seizures and other neurologic symptoms (Genvresse et al., 1999). Methotrexate increases the concentration of homocysteine, which is oxidatively metabolized to the excitatory amino acid neurotransmitters homocysteic acid and cysteine sulfinic acid. Homocysteine also damages the vascular endothelium (Quinn et al., 1997). Seizures have been reported with intrathecal and intraventricular administration of methotrexate and cytosine arabinoside as well (Lee et al., 1997; Resar et al., 1993). Neuroimaging studies, particularly MRI scans of the brain, show diffuse white matter lesions, some of which may enhance, or may demonstrate a more focal pattern (Lovblad et al., 1998). Aminophylline has been reported to be an effective treatment for methotrexate-induced subacute neurotoxicity (Bernini et al., 1995).

Cisplatin. Seizures following intravenous cisplatin are mainly due to hypomagnesemia and hypocalcemia

and thus are easily prevented by magnesium and, if necessary, calcium supplementation during the chemotherapy infusion (Bachmeyer et al., 1996; Fuse-Nagase et al., 1997).

5-Fluorouracil. Severe neurotoxicity with seizures, encephalopathy, syncope, ataxia, motor neuropathy, and demyelinating lesions evident on MRI scan has been reported in patients treated with 5-fluorouracil (5-FU). These patients had an underlying dihydropyrimidine dehydrogenase deficiency, an enzyme that is responsible for the rate-limiting step of 5-FU catabolism. This deficiency increased binding of 5-FU to thymidylate synthetase and incorporation into RNA (Shehata et al., 1999).

Pre-existing renal disease, which alters the clearance of chemotherapeutic agents, has been implicated in neurotoxicity, with seizures caused by treatment with *chlorthalidone* and *cytosine arabinoside*. Decreasing the dose of the chemotherapeutic agent is recommended for such patients (Salloum et al., 1997; Smith et al., 1997).

Ifosfamide (ifosfamide). Ifosfamide, commonly used to treat sarcomas, medulloblastoma, and other pediatric and adult tumors, can cause severe neurotoxicity manifested by coma and seizures (Bhardwaj and Badesha, 1995; Gieron et al., 1988).

Paclitaxel (Taxol). Paclitaxel is highly active against ovarian, breast, and other cancers (lung, uterine). It is a mitotic spindle inhibitor, and it exerts its major neurotoxic effect on peripheral nerves. Recent reports link paclitaxel-induced encephalopathy with seizures, particularly in those patients treated with high doses (Nieto et al., 1999; Perry and Warner, 1996). Reversible encephalopathy and seizures have also been reported with vincristine. A brain biopsy specimen in one reported case revealed neurotubular dissociation (Hurwitz et al., 1988).

Cyclosporin. Immunosuppressant drugs such as cyclosporin are given to bone marrow transplant recipients to prevent rejection. These agents have been reported to induce seizures in patients pretreated with busulfan or platinum compounds (Ghany et al., 1991).

Biologic Response Modifiers. Encephalopathy and seizures have been reported after the administration

of interferon, interleukin-2 (IL-2), lymphokine-activated killer cells, and some colony-stimulating factors (Dierckx et al., 1985; Karp et al., 1996; Meyers et al., 1991). Transient lesions in the occipital poles, cerebellum, and centrum semiovale have been described in patients treated with IL-2 who developed focal neurologic problems, including seizures (Karp et al., 1996).

Intratumoral Therapies. Intratumoral therapies seek to decrease systemic toxicity of a chemotherapeutic agent through a high level of regional drug delivery. However, the risk of causing seizures is higher in those patients with a prior history of tumor-related seizures. Increased frequency of seizures was noted in patients treated with intratumoral BCNU Wafers (Gliadel) (Brem et al., 1995); seizures typically occurred in the first 5 days after surgery, although they were also observed at 20 to 100 days after implantation.

Seizures Related to Other Drugs

Narcotics. Cancer patients often require narcotics for control of pain. Narcotics occasionally cause neurotoxicity and seizures. Specific drugs associated with the occurrence of seizures are meperidine (Demerol Hydrochloride), propoxyphene (Darvon), and, rarely, morphine sulfate. In the case of meperidine, the metabolite normeperidine has been implicated. Renal dysfunction may contribute to, but is not the determining factor for, the accumulation and neuroexcitatory effect of normeperidine (Goetting and Thirman, 1985; Kaiko et al., 1983; Szeto et al., 1977). Seizures have been reported in patients who have been treated with an intravenous morphine solution containing sodium bisulfate as a preservative (Meisel and Welford, 1992). An intrathecal or intraventricular morphine bolus can also cause seizures (Kronenberg et al., 1998). Propoxyphene has been reported to cause status epilepticus.

Antiemetics. Some neuroleptics used as antiemetics in conjunction with chemotherapy (phenothiazines, butyrophenones) have been reported to induce seizures. This phenomenon appears to be dose related. The newer antiemetics, such as ondansetron, cause less neurotoxicity.

Antibiotics. Many cancer patients with neutropenia and depressed immune systems due to malignancy and chemotherapy receive broad-spectrum antibiotics or multiple antibiotics. Some of these have been associated with encephalopathy and seizures. Most often implicated are the quinolones and betalactams.

The neurotoxicity of the quinolones is dose related. Experimental studies have shown that this is because gamma-aminobutyric acid-like substituents in the structure of quinolones act as antagonists at the gamma-aminobutyric acid receptors (Akahane et al., 1989). Renal failure and the presence or history of brain metastases are contributing factors (Walton et al., 1997).

Of the betalactams, imipenem/cilastatin (Primaxin) is the most neurotoxic. Betalactam neurotoxicity seems to be due to an increased concentration of the drug in brain tissue when it is given in high doses or given to patients with impaired renal function or caused by alterations in the blood-brain barrier due to infection or malignancy (Bodey et al., 1987). An impaired mechanism for clearance of the drug from brain tissue may be involved, but this has not yet been documented (Schliamsner et al., 1991).

Methylphenidate (Ritalin). Patients with brain tumors or systemic cancer often experience fatigue, lethargy, depressed mood, and overall neurobehavioral slowing. These symptoms can be caused by the brain tumor itself or by the effects of RT and chemotherapy. Methylphenidate has been shown to improve patients' energy level and function (Meyers et al., 1998; Weitzner et al., 1995). There is some concern, however, that the drug may increase the frequency of seizures in patients who have a history of epilepsy or seizures due to the presence of brain tumor. This association has been demonstrated by results from studies of children with epilepsy and attention deficit hyperactivity disorder (Gross-Tsur et al., 1997). In contrast, a study of patients with brain injury and epilepsy suggests that methylphenidate may actually decrease the frequency of seizures (Wroblewski et al., 1992). In sum, the benefit of methylphenidate therapy for cancer patients with neurobehavioral slowing outweighs the remote risk of seizures.

Radiologic Contrast Medium. Intravenous contrast media used for CT scans of the brain have been reported to trigger either focal or generalized seizures

(Avrahami et al., 1987), particularly in those patients who have primary or metastatic brain tumors. Contrast-induced seizures are caused by an increased susceptibility to seizures and increased permeability of the blood-brain barrier in these patients, and they are possibly a direct toxic effect of the agents used (Avrahami et al., 1989; Fischer, 1980).

Seizures with Metabolic Causes

Metabolic abnormalities are the most common cause of altered levels of consciousness in cancer patients. Hyponatremia, hypoglycemia, hypomagnesemia, hypocalcemia, and hypoxia lower the seizure threshold. Seizures caused by metabolic abnormalities tend to be generalized. The accompanying cerebral dysfunction is diffuse, even in the rare case of a focal or complex partial seizure (Cascino, 1993; Stein and Chamberlain, 1991).

Hyponatremia. Hyponatremia in cancer patients can be caused by volume depletion or volume overload, by drugs, or by a malignancy, such as occurs with paraneoplastic syndrome. Intravascular volume depletion occurs as a result of poor fluid intake, fluid loss with emesis, or retention of fluid in the abdominal cavity (ascites), either neoplastic or due to congestive heart failure. Aggressive hydration to enhance the renal clearance of some chemotherapeutic drugs (platinum, methotrexate) causes dilutional hyponatremia (McDonald and Dubose, 1993).

The syndrome of inappropriate antidiuretic hormone (SIADH) is another common cause of hyponatremia in patients with cancer. As in paraneoplastic syndrome, it occurs most commonly in patients with small cell lung carcinoma and also in those with Hodgkin's lymphoma, non-small cell lung carcinoma, and cancer of the pancreas, colon, prostate, or adrenal cortex. Small cell lung carcinoma cells produce arginine-vasopressin-like and atrial natriuretic-like factors, two hormones implicated in paraneoplastic SIADH (Franck et al., 1987; Vanhees et al., 2000). For other types of cancer, the production of ectopic hormones is less well documented.

SIADH also occurs in those patients with leptomeningeal metastases, tumors involving the hypothalamus, and basilar meningitis. Drugs that can cause the syndrome are carbamazepine, neuroleptics (haloperidol [Haldol]), tricyclic antidepressants, and cytotoxics (Vinca alkaloids, cyclophosphamide). Cis-

platin can cause SIADH with secondary seizures (Ritch, 1988). Diagnosis is made on the basis of laboratory findings of hyponatremia, hypo-osmolality of the serum, and increased urine osmolality. Renal, hepatic, adrenal, and pituitary function are normal.

It is important to correctly diagnose the cause of hyponatremia to treat it appropriately. Hydration with normal saline solution corrects the problem of fluid depletion. Fluid restriction, sodium supplementation, and sometimes diuretics are indicated to treat fluid overload. The treatment of SIADH consists of restricting fluids, administering demeclocycline, and identifying and, if possible, removing the cause. Paraneoplastic SIADH usually resolves if the tumor can be removed or if it responds to radiation or chemotherapy. The syndrome may recur, indicating tumor recurrence (McDonald and Dubose, 1993; Richardson 1995; Ritch, 1988).

Hypoglycemia. Hypoglycemia occurs in cancer patients who receive total parenteral nutrition and results from either the insulin in the solution or withdrawal of total parenteral nutrition. Other causes are malnutrition and pancreatic tumors (insulinoma) (Daggett and Nabarro, 1984; Hazard et al., 1985). Seizures can occur with blood glucose levels below 40 mg/dL; they are usually preceded by diaphoresis, tremor, a sensation of hunger, and nervousness.

Hypocalcemia and Hypomagnesemia. Hypocalcemia and hypomagnesemia are two electrolyte abnormalities that have similar effects on the nervous system. Hypocalcemia and hypomagnesemia occur in patients who receive intensive chemotherapy, especially cisplatin, with overhydration (Bachmeyer et al., 1996; Fuse-Nagase et al., 1997). Hypocalcemia has also been reported in patients treated with amphotericin B. It occurs less commonly with malnutrition or in patients with secondary hypoparathyroidism following treatment for thyroid cancer. Seizures are a common manifestation of hypocalcemia because of the increased excitability of the cerebral cortex. Other clinical manifestations of hypocalcemia and hypomagnesemia, including tremor, carpedal spasm (tetany), and myoclonus, can sometimes be confused with motor seizures.

Hypoxia. Hypoxia is another potential, although less common, cause of seizures in cancer patients. Acute hypoxia occurs with pulmonary embolism, prolonged

syncope, massive pneumonitis, rapid progression of lung tumors, or metastatic lymphangitic spread. Patients with pulmonary fibrosis secondary to chemotherapy (bleomycin, nitrosoureas) or RT are also at risk.

Seizures with Infectious Causes

Cancer patients are very susceptible to infections, and seizures occur in those patients who have systemic infections or infectious processes in the CNS. Patients undergoing high-dose chemotherapy with bone marrow transplant are at particular risk. Central nervous system infections associated with seizures can be caused by viruses (herpes simplex virus, cytomegalovirus, herpes zoster virus); bacteria, including common pathogens and opportunistic agents (*Listeria*, *Mycobacterium*); fungi (*Aspergillus*, *Cryptococcus*); or parasites (*Toxoplasma*) (Bosi et al., 1998; Pruitt, 1991). Clinically, patients with seizures caused by infections present with confusion, altered level of consciousness (encephalitis), meningitic signs, or, in the case of abscess, focal findings.

Seizures with Vascular Causes

Cancer patients have both embolic and thrombotic strokes. The pathogenesis of cerebrovascular events in these patients includes cancer- and treatment-related causes (Graus et al., 1985).

Embolic Stroke. Embolic events can occur in the presence of cardiac arrhythmia, which occurs in patients treated with paclitaxel, in those with cardiomyopathy secondary to doxorubicin, and in cancer-associated marantic endocarditis (Rosen and Armstrong, 1973).

Thrombotic Stroke. Thrombotic strokes are observed in patients who have hypercoagulability syndromes, paraneoplastic phenomena associated with pancreatic cancer, breast carcinoma, and other malignancies (Collins et al., 1975; Patronas and Argyropoulou, 1992). Stroke in cancer patients can be caused by carotid artery stenosis following RT to the neck for treatment of head and neck tumors or by compression from neoplastic adenopathy. Radiotherapy to the brain can induce vasculopathy, another potential cause of ischemic stroke. Thrombotic and hemorrhagic strokes with secondary seizures have been

reported in children whose leukemias were treated with L-asparaginase. L-asparaginase causes deficiencies of antithrombin, plasminogen, fibrinogen, and factors IX and XI (Priest et al., 1980). Chemotherapy-induced vascular events may be transient, and MRI scans may show areas of ischemia in the watershed distribution (Pihko et al., 1993).

Venous Sinus Thromboses. Venous sinus thromboses can occur with the secondary venous infarctions that can be caused by tumor invasion or metastatic or infectious meningitis. Venous infarctions are most often hemorrhagic.

Parenchymal and Intratumoral Hemorrhage. New-onset seizure or an increase in seizure frequency occurs in those patients with hemorrhage into a primary or metastatic brain tumor. Of the metastatic tumors, melanoma, renal cell carcinoma, and choriocarcinoma are most commonly associated with hemorrhages.

Spontaneous Subarachnoid Hemorrhage. While subarachnoid hemorrhage may occur in patients who have a malignancy, it may not always be possible to elucidate the pathogenesis of the process. One cause for subarachnoid hemorrhage or small cortical parenchymal hemorrhage is CNS aspergillosis. It is important to appreciate that subarachnoid hemorrhages can recur along with seizures as part of their clinical manifestation.

Traumatic Subdural or Subarachnoid Hemorrhage. These hemorrhages can occur in cancer patients who are thrombocytopenic or who develop a low-grade disseminated intravascular coagulation syndrome. In such cases, even minor trauma may cause hemorrhage.

Diagnosis

The diagnosis of seizures in cancer patients is made on the basis of a detailed history, physical and neurologic examinations, laboratory tests, neuroimaging results, and electroencephalographic findings. When taking the patient's history, the clinician must try to obtain an accurate description of the ictal event: timing of the event in relation to the diagnosis of tumor and the treatment for cancer, the presence or absence of aura, elements of focality, the behavior of the pa-

tient immediately before the seizure, the duration of the event and of the post-ictal period, and whether or not there are residual mental status changes or focal neurologic deficits. The clinician should also try to obtain information about the administration of all medications before the seizure and the presence of any signs of infection. It is important to elicit the past medical history, focusing on prior history of seizures, cardiac disease, pulmonary disease, diabetes, and head trauma. Common symptoms associated with seizures are headache, paresthesias, diaphoresis, difficulty breathing, gastric discomfort, and occasionally blurring of vision.

The physical and neurologic examinations will help to identify the cause(s) of the seizure. The presence of focal neurologic deficits suggests that the patient has a focal intracranial lesion (parenchymal or dural/meningeal), either neoplastic, infectious (abscess, empyema), hemorrhagic, or vascular. Focal leukoencephalopathy secondary to RT or chemotherapy can also present with focal deficits. Altered level of consciousness, myoclonus, and asterixis suggest metabolic disturbances.

The first seizure in a cancer patient should prompt laboratory tests, including complete blood cell count, with differential and platelet counts; chemistry profile; assay of magnesium level; blood and urine cultures; and blood levels for drugs such as cyclosporin, methotrexate, aminophylline, ethanol, and, if appropriate, street drugs.

Contrast-enhanced gadopentetic acid-enhanced MRI scan or CT scan of the brain can usually identify intracranial lesions, leptomeningeal disease, strokes, and hemorrhages. The extent of edema and mass effect can also be evaluated.

Lumbar puncture is indicated for the diagnosis of meningitis, leptomeningeal metastases, and subarachnoid hemorrhage. It must be performed with great caution in patients who have an intracerebral mass or thrombocytopenia. Platelet transfusion may be necessary during the procedure.

Electroencephalography helps to identify the seizure focus and differentiate between disease processes. Specific findings on electroencephalograms occur in herpesvirus encephalitis (periodic lateralized epileptiform discharges in the temporal lobes) and in some metabolic encephalopathies (triphase waves).

The differential diagnosis must be made with other paroxysmal events, such as syncope, myoclonic jerks,

tetany, transient encephalopathy, transient ischemic attacks, and panic attacks, which can all mimic seizures.

Treatment

An algorithm for the management of seizures in cancer patients is presented in Figure 20–1. To decide which therapy to use for ictal events, the neurologist must answer two important questions: whether the event was a seizure and whether anticonvulsants are indicated.

If the patient is in status epilepticus, efforts should focus on stopping the seizures. Airway patency must be established, and intravenous therapy with benzodiazepines (lorazepam, diazepam) and antiepileptic drugs (phenytoin, phenobarbital) must be initiated. If the work-up indicates a toxic or metabolic cause for the status epilepticus, antiepileptic drugs can be discontinued once the seizures have stopped and their cause has been eliminated. Any drugs known to be epileptogenic must be discontinued, the metabolic abnormalities must be corrected, and appropriate antibiotic therapy must be instituted for infection, avoiding quinolones and betalactams.

Long-term anticonvulsant treatment is indicated for patients with a pre-existing seizure disorder, primary or metastatic brain tumors, or other parenchy-

mal lesions. The use of prophylactic antiepileptic drugs in patients with brain tumors who do not have seizures is controversial (Cohen et al., 1988). In such patients, antiepileptic drugs may cause adverse effects. Whether or not to use antiepileptic drugs is determined by the patient's condition and hepatic and renal function and by the concurrent administration of drugs that interfere with antiepileptic drugs' metabolism and excretion.

In patients with altered mental status, antiepileptic drugs must be administered parenterally. The drugs of choice are benzodiazepines, phenytoin, or phenobarbital.

For treatment of generalized seizures, phenytoin is usually the first drug administered. For complex partial seizures, carbamazepine may be the first-line drug. Phenobarbital is the drug of choice for children.

Phenytoin (Dilantin)

Phenytoin is the most widely used antiepileptic drug in the United States. A known effective anticonvulsant, it has several advantages: It can be administered by multiple routes (oral, intravenous, through a gastric tube in its elixir form); it has a long half-life, which allows once-a-day dosing; and it is inexpensive.

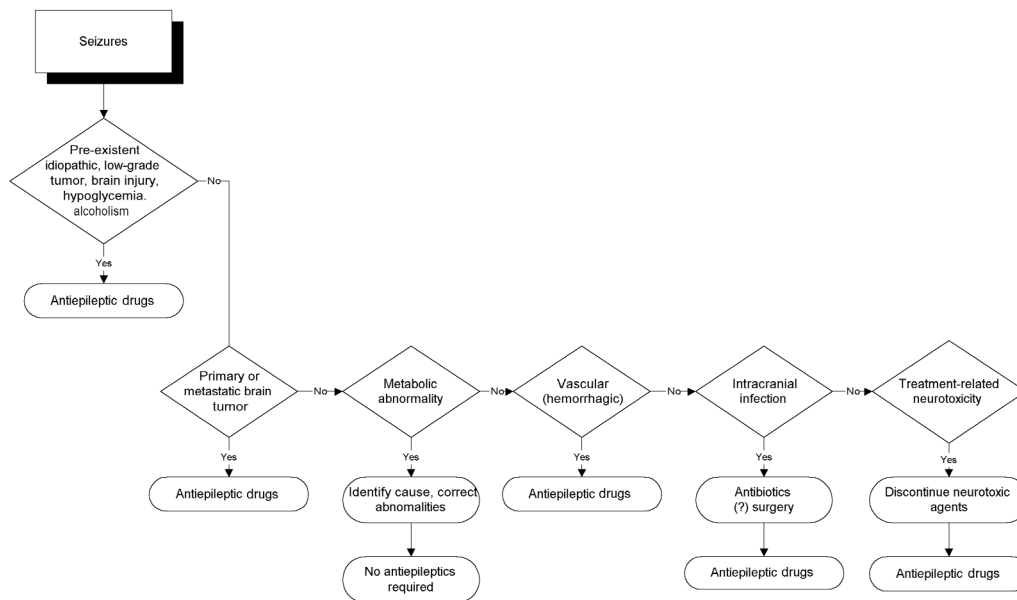


Figure 20–1. An algorithm for the management of seizures in the neuro-oncologic patient.

Problems associated with phenytoin are related to its pharmacokinetics. It is metabolized in the liver, and its serum levels are influenced by liver disease (metastatic or noncancer related) as well as by its multiple drug interactions (DeMonaco and Lawless, 1983; Gattis and May, 1996; Ghosh et al., 1992). Dexamethasone, commonly used in patients with primary and metastatic brain tumors as well as an adjuvant antiemetic in patients receiving chemotherapy, has been demonstrated to lower phenytoin levels (Gattis and May, 1996; Lackner, 1991). Platinum-containing chemotherapy regimens have been reported to decrease phenytoin levels to as low as 25% of the initial therapeutic level, with return to baseline after discontinuation of chemotherapy. Procarbazine, a chemotherapeutic agent related to disulfiram, can increase the level of phenytoin. Anticonvulsants also increase the risk of procarbazine hypersensitivity reactions (Lehmann et al., 1997). The phenytoin dose needs to be adjusted and the levels monitored closely in those patients receiving chemotherapy to avoid under dosing and toxic effects (Neef and de Voogd-van der Straaten, 1988; Grossman et al., 1989; Ghosh et al., 1992). Phenytoin also increases clearance and may thus decrease the efficacy of chemotherapeutic agents such as busulfan, paclitaxel, topotecan and related drugs (Grossman et al., 1998; Hassan et al., 1993; Zamboni et al., 1998). Because of decreased protein binding and increased free plasma drug levels, the dose must be decreased for patients who are being treated with warfarin or cimetidine.

Both total and free phenytoin levels should be monitored in patients who have impaired renal function because phenytoin excretion may be impaired. Seizures can occur in cancer patients receiving phenytoin when subtherapeutic levels of the drug are administered, and they can also occur as a manifestation of phenytoin toxicity. Phenytoin can cause allergic reactions, usually a cutaneous rash. Severe reactions, including Stevens-Johnson syndrome, have been described in patients being weaned from corticosteroids while receiving RT to the brain (Delattre et al., 1988).

In vitro, but not in vivo, studies indicated a possible radiosensitizing effect of phenytoin on astrocytoma cells (Lordo et al., 1987). Phenytoin and other enzyme inducers were reported to have a protective effect in patients receiving busulfan, reducing its neurotoxicity and myelotoxicity. Phenytoin is now used for seizure prophylaxis in patients receiving chemo-

therapy with busulfan (Fitzsimmons et al., 1990). Phenytoin was also shown to selectively enhance the cytotoxicity of microtubule inhibitors, such as Vinca alkaloids; this activity is presently under investigation for potential clinical use (Ganapathi et al., 1993).

Carbamazepine (Tegretol)

Carbamazepine and its newer derivative oxcarbazepine (Trileptal) is the anticonvulsant of choice for patients with complex partial seizures, and it is used as a second-line antiepileptic drug for patients with generalized seizures who either did not have adequate seizure control with phenytoin or developed allergic reactions to it. When administered together with phenytoin, carbamazepine decreases the phenytoin level. It can only be administered orally or through a gastrostomy tube and therefore cannot be used in emergency situations. The main difficulty with using carbamazepine in cancer patients is its myelotoxic effect, which causes neutropenia, lymphopenia, and aplastic anemia (Silverman and Chapron, 1995). These problems limit its use in patients who are receiving chemotherapy. Furthermore, carbamazepine levels are decreased by chemotherapeutic drugs such as platinum (Jain, 1993). Carbamazepine also causes SIADH. Like phenytoin, carbamazepine can cause allergic reactions, including Stevens-Johnson syndrome.

Valproic Acid

Valproic acid and its derivative divalproex sodium (Depakote) are used for patients with seizures that are not controlled by phenytoin. The drugs are administered orally and are metabolized in the liver. When administered together with phenytoin, valproate can either decrease or increase phenytoin levels. Methotrexate has been reported to cause an acute decline in the level of serum valproate (Schroeder and Ostergaard, 1994). Reported toxic effects that limit its use in cancer patients are hepatotoxicity, prolonged bleeding time, and dose-dependent thrombocytopenia.

Phenobarbital

Phenobarbital remains the drug of choice for controlling seizures in children. It is mainly used as an adjunct to phenytoin or for adult patients for whom

other anticonvulsants have failed. Its main side effect is somnolence, although some patients experience arthralgias or allergic reactions.

Gabapentin (Neurontin)

A new class of antiepileptic drug, GABA agonists, has recently been released to the marketplace, and there is not much experience with their use by cancer patients. Neurontin is purported to cause fewer side effects than conventional antiepileptic drugs, but there have been no studies to evaluate its interactions, if any, with chemotherapeutic agents. Because it has so few side effects, it is commonly used in combination with phenytoin, carbamazepine, or valproate for brain tumor patients with refractory complex partial seizures.

Lamotrigine (Lamictal)

Lamotrigine is a new, structurally unique, anticonvulsant that acts on voltage-dependent sodium channels, resulting in decreased release of excitatory neurotransmitters. It is indicated for treatment of partial seizures but can cause severe dermatologic side effects and myelotoxicity. It has known interactions with other anticonvulsants, but to date there are no reports of interactions with chemotherapeutic drugs. Lamotrigine is a dehydrofolate reductase inhibitor and should not be used by patients treated with methotrexate and other antimetabolites.

Topiramate (Topamax)

Topiramate is another new anticonvulsant used as adjunctive therapy for partial seizures. It acts on sodium channels and as a GABA agonist. It produces no significant drug interactions, and its main side effect is psychomotor slowing. Topamax may cause leukopenia.

Gabitril (Tiagabine)

Gabitril is another new GABA-ergic anticonvulsant, which is indicated as an adjunctive treatment of complex partial seizures. It has no significant drug interactions, and it can be safely used with enzyme-inducing drugs. Rarely, it may cause anemia and thrombocytopenia. These new drugs can be used by patients with known allergy to the first-line anticon-

vulsants and as adjuncts for better seizure control by patients who fail anticonvulsant monotherapy.

Conclusions

Seizures are a common neurologic problem in patients with systemic and CNS malignancies and may have multiple etiologies. Examination should be aimed at identifying and treating all of its possible causes. The treatment of seizures in cancer patients must be individualized, and metabolic factors and drug interactions must be taken into consideration when anticonvulsant therapy is initiated.

SYNCOPE

Syncope is defined as a sudden transient loss of consciousness and postural tone with spontaneous recovery. The frequency of syncope in cancer patients is not well documented. Presyncope, with premonitory symptoms but without loss of consciousness ("faint feeling"), is probably even more common (Plum and Posner, 1982). Syncope occurs because of a transient interruption of cerebral blood flow. Common presyncopal symptoms are dizziness, lightheadedness, palpitations, diaphoresis, and, occasionally, paresthesias.

Etiology

The etiology of syncope in cancer patients is presented in Table 20-2. As in the case of seizures, several etiologic factors may contribute to syncope in cancer patients, the most common being orthostatic hypotension, with cardiac causes assuming a secondary role. Other causes are drugs, vasovagal reactions, and cerebrovascular disease (Kapoor, 1991, 1992; Manolis et al., 1990).

Orthostatic Hypotension

Orthostatic hypotension is commonly present in the terminal stages of cancer in those patients who are suffering from malnutrition and dehydration. It also occurs in those who become dehydrated from emesis caused by chemotherapy. Patients with severe anemia often present with syncope or presyncope caused by insufficient oxygenation of the brain rather than from volume depletion. The drop in blood pressure

Table 20-2. Etiology of Syncope in Patients with Malignancy

<i>Etiologic Factors</i>	<i>Causes</i>
Orthostatic hypotension	
Volume depletion	Dehydration, hemorrhage
Dysautonomia	Platinum compounds, Vinca alkaloids, taxanes, diabetes
Drug induced	Tricyclic antidepressants, vasodilators, diuretics
Neurotoxicity (drug induced)	Chemotherapeutic agents (fluorouracil, Vinca alkaloids, platinum compounds, taxanes), CNS depressants (barbiturates), biologic response modifiers
Hypoglycemia	Nutritional, pancreatic tumors (insulinoma)
Cardiac	
Reflex cardiogenic	Parapharyngeal tumors, radiation therapy to neck
Pump failure	Myocardial ischemia (mediastinal radiation, atherosclerosis), cardiomyopathy (adriamycin, graft-versus-host disease, viral)
Cardiac arrhythmia	Chemotherapy (paclitaxel, interleukin-2), mediastinal radiation, pre-existing cardiac disease
Pulmonary flow obstruction	Pulmonary embolism
Vasovagal	Micturition, coughing, swallowing, strong emotional stimuli
Cerebrovascular	Vertebrobasilar insufficiency

with change in position is accompanied by an increased heart rate. Chemotherapeutic agents such as cisplatin and Vinca alkaloids cause a peripheral neuropathy with dysautonomia. The heart rate does not increase significantly with the drop in blood pressure in patients who have this condition.

Another common cause of orthostatic hypotension in cancer patients is related to drugs such as diuretics and antidepressants. The pathogenetic mechanism of orthostasis in patients taking diuretics is intravascular volume depletion, whereas antidepressants, neuroleptics, and some antiemetics cause an anticholinergic effect. Hypotension with possible presyncope or syncope is a common side effect of biologic agents such as interferon, IL-2, and tumor necrosis factor. Orthostatic presyncope and syncope also occur in patients with severe infections that cause high fever and dehydration.

Drug Related

Syncope can be a side effect of medications, even in the absence of other etiologic factors. The mechanisms are orthostatic hypotension either through volume depletion (diuretics, mannitol), vasopressor effects (biologic response modifiers), anticholinergic effects (antidepressants), cardiac arrhythmia (paclitaxel, intravenous phenytoin), or peripheral neuropathy (vincristine, paclitaxel, platinum compounds).

Syncope is also part of the spectrum of direct neurotoxic effects of chemotherapeutic drugs such as fluorouracil (Hook et al., 1992; Shehata et al., 1999). Biologic response modifiers and colony-stimulating factors also cause hypotension with syncope or near-syncope (Lieschke et al., 1989).

Hypoglycemia

Syncope in hypoglycemic patients has a fairly typical clinical presentation, which suggests its diagnosis. It is preceded by a sensation of hunger. The patient becomes irritable, tremulous, and diaphoretic and may complain of dimming vision. The skin becomes pale. Loss of consciousness is brief and is usually not followed by confusion; however, with severe hypoglycemia, there may be associated seizure activity. Hypoglycemia occurs in patients who have insulinoma, malnutrition, and insulin-dependent diabetes and can be caused by insulin overdosing from total parenteral nutrition. The symptoms of patients with insulinoma typically occur in the morning, before breakfast, or between meals (Daggett and Nabarro, 1984; Hazard et al., 1985).

Cardiovascular Causes

Syncope is a common manifestation of cardiac disease. Cancer patients can experience the same prob-

lems that patients without malignancy do. The main pathogenetic mechanisms for syncope of cardiac origin are pump failure, heart blocks, and arrhythmias.

Pump failure occurs in myocardial infarction or cardiomyopathy. In cancer patients, cardiomyopathy can be caused by chemotherapy with anthracyclines, especially *daunorubicin*, which may be irreversible. Other cardiotoxic chemotherapeutic agents are *mitoxantrone* and *estramustin*. The risk for cardiac disease increases if such drugs are administered following RT to the chest and mediastinum. Viral myocarditis in the immunosuppressed patient and graft-versus-host disease following allogeneic bone marrow transplant are other causes of heart failure. Heart failure patients usually have symptoms suggestive of myocardial ischemia before syncope: chest pain, dyspnea, and signs of heart failure.

Heart blocks and cardiac arrhythmias in cancer patients are usually caused by a pre-existing cardiac condition. Arrhythmias do occasionally result from paclitaxel or IL-2 therapy. Several case reports of syncope describe cardiac arrhythmias, coronary artery stenosis, and defective cardiovascular reflexes in patients who were treated with RT to the mediastinum or neck (de Waard et al., 1996; Mary-Rabine et al., 1980; Shapiro et al., 1996). Syncope occasionally occurs after obstruction of pulmonary flow caused by pulmonary embolism.

Cerebrovascular Causes

Syncope can be a manifestation of cerebrovascular disease in the anterior or posterior circulation and may or may not be associated with focal neurologic deficits. Possible causes of altered cerebral blood flow in cancer patients include compression of the carotid artery by tumor, stenosis of the subclavian or carotid arteries following RT to the chest or neck, and thrombotic or embolic events. When syncope occurs after elevation or exertion of the left arm, a subclavian steal must be suspected, and blood pressure should be measured in both arms.

Tumor Related

Patients with head and neck tumors, thyroid tumors, and cervical lymphadenopathy can develop recurrent syncope related to carotid sinus hypersensitivity. Syncope in patients with head and neck tumors can occur through several mechanisms: glossopharyngeal

neuralgia–asystole syndrome, carotid sinus syndrome, and glossopharyngeal-related reflex cardiogenic syncope without neuralgic pain (Cicogna et al., 1993; Dykman et al., 1981; Wang and Ng, 1995). Nasopharyngeal and parapharyngeal carcinomas cause these syndromes. In these patients, syncope does not respond to medical management or in some cases to pacemaker insertion. Syncope may resolve after treatment of the tumor or may require intracranial intervention to resect the glossopharyngeal nerve.

Vasovagal Response

Vasovagal syncope is one of the most common types of syncope in young adults, and patients usually present with a history of prior syncopal episodes. Vasovagal syncope occurs in response to stress, pain, fear, and heat and is preceded by symptoms such as palpitations, queasiness, nausea, diaphoresis, and abdominal discomfort. Incontinence is uncommon. The underlying pathophysiologic mechanism is thought to be a reflex withdrawal of sympathetic tone (Bezold-Jarisch reflex), indicated clinically by tachycardia, followed by bradycardia, pallor, and hypotension. Syncope that occurs during micturition or defecation (situational syncope), typically after a long period of bed rest, is more common in men than in women.

Diagnosis

The diagnosis of syncope is made primarily on the basis of the patient's clinical presentation (if the episode is witnessed) or an accurate and detailed history. The history should include data on the patient's complaints before the loss of consciousness, appearance of the patient (skin pale or flushed, diaphoresis, breathing pattern), duration of the episode, associated seizure activity, incontinence, and the presence or absence of confusion. Information should also be obtained about the patient's past medical history with regard to cardiac disease, hypertension or hypotension, diabetes and hypoglycemia, type of cancer, psychiatric history, medications, and circumstances of the event (micturition or defecation, crowded or overheated area, pain, stress). The physical and neurologic examinations, if feasible at or near the time of the event, can reveal the presence of hypotension, arrhythmia, or focal findings suggestive of a vascular or neoplastic brain lesion.

Examination should include measurement of blood pressure and heart rate in both supine and standing positions and in both arms to determine the presence of position hypotension or the subclavian steal syndrome. Auscultation of the heart can reveal arrhythmias and/or cardiac valve abnormalities. Cardiac monitoring, echocardiogram, and laboratory tests also help the clinician make the diagnosis. Laboratory tests should include hemoglobin, hematocrit, white blood cell count, differential count, and platelet count to rule out anemia and infection; electrolyte, glucose, calcium, and magnesium levels; drug levels when appropriate (psychotropics and antidepressants, opiates, barbiturates); and blood and urine cultures when infection is suspected.

When focal neurologic deficits are present, a CT or MRI scan of the brain is indicated. Electroencephalography is helpful in the differential diagnosis with seizures, especially in patients with focal neurologic deficits if seizure activity has been witnessed during syncope (Hoefnagels et al., 1991). Hypoglycemic syncope and the syncope in Adams-Stokes syndrome (third-degree heart block) can be associated with seizure activity.

Upright tilt-table testing is useful for diagnosing vasovagal syncope. It is performed by measuring blood pressure and heart rate (continuous electrocardiogram) in the supine position and then bringing the patient suddenly to an upright position on the tilt table and maintaining the upright position until presyncope or syncope occurs in association with hypotension and/or tachycardia. The test can be performed with or without infusion of isoproterenol (Kapoor, 1992). Lumbar puncture is usually not indicated except when meningitis or meningeal metastases are considered.

The differential diagnosis must be made taking into account all factors that can cause altered level of consciousness, including seizures, encephalopathy, cerebral ischemia, brain concussion, and drug or alcohol intoxication. In these cases, loss of consciousness is of longer duration, and the history and physical examinations establish the diagnosis. Psychiatric conditions such as conversion reactions, generalized anxiety disorder with hyperventilation, and panic attacks must also be considered. Information about psychotropic and antidepressant medications should be obtained from patients who have a psychiatric history.

Treatment

Syncope is a brief, usually fully reversible, episode of loss of consciousness that generally does not require specific treatment. However, when the cause of syncope is a life-threatening condition such as a heart block, malignant arrhythmia, or pulmonary embolus, close monitoring and urgent appropriate treatment must be instituted. Insertion of a cardiac pacemaker and, in some cases, intracranial section of the glossopharyngeal nerve are necessary. In simple syncope, the elimination of the causative agent(s) usually prevents further occurrences. Supportive therapy, maintenance of good nutritional status, hydration or blood transfusions to maintain adequate intravascular volume, correction of hypoglycemia and electrolyte abnormalities, and discontinuation of offending drugs can prevent the occurrence of syncope in cancer patients (Benitez del Rosario and Salinas Martin, 1997).

REFERENCES

- Ahern GL, O'Connor M, Dalmau J, et al. 1994. Paraneoplastic temporal lobe epilepsy with testicular neoplasm and atypical amnesia. *Neurology* 44:1270-1274.
- Akahane K, Sekiguchi M, Une T, Osada Y. 1989. Structure-epileptogenicity relationship of quinolones with special reference to their interaction with gamma-aminobutyric acid receptor sites. *Antimicrob Agents Chemother* 33:1704-1708.
- Antonini G, Ceschin V, Morino S, et al. 1998. Early neurologic complications following allogeneic bone marrow transplant for leukemia: a prospective study. *Neurology* 50:1441-1445.
- Avrahami E, Weiss-Peretz J, Cohn DF. 1987. Focal epileptic activity following intravenous contrast material injection in patients with metastatic brain disease. *J Neurol Neurosurg Psychiatry* 50:221-223.
- Avrahami E, Weiss-Peretz J, Cohn DF. 1989. Epilepsy in patients with brain metastases triggered by intravenous contrast medium. *Clin Radiol* 40:422-423.
- Bachmeyer C, Decroix Y, Medioni J, et al. 1996. [Hypomagnesemic and hypocalcemic coma, convulsions and ocular motility disorders after chemotherapy with platinum compounds]. *Rev Med Interne (Paris)* 17:467-469.
- Bartolomei JC, Christopher S, Vives K, Spencer DD, Piepmeier JM. 1997. Low-grade glioma of chronic epilepsy: a distinct clinical and pathological entity. *J Neurooncol* 34:79-84.
- Benitez del Rosario MA, Salinas Martin A. 1997. Hydration for control of syncope in palliative care. *J Pain Symptom Manage* 14:5-6.
- Bernini JC, Fort DW, Griener JC, Kane BJ, Chappell WB, Kamen BA. 1995. Aminophylline for methotrexate-induced neurotoxicity. *Lancet* 345:544-547.

- Bhardwaj A, Badesha PS. 1995. Ifosfamide-induced nonconvulsive status epilepticus. *Ann Pharmacother* 29:1237-1239.
- Blaney SM, Balis FM, Poplack DG. 1991. Pharmacologic approaches to the treatment of meningeal malignancy. *Oncology (Huntingt)* 5:107-116.
- Bodey GP, Elting L, Jones P, Alvarez ME, Rolston K, Fainstein V. 1987. Imipenem/cilastatin therapy of infections in cancer patients. *Cancer* 60:255-262.
- Bosi A, Zazzi M, Amantini A, et al. 1998. Fatal herpesvirus 6 encephalitis after unrelated bone marrow transplant. *Bone Marrow Transplant* 22:285-288.
- Brem H, Piantadosi S, Burger PC, et al. 1995. Placebo-controlled trial of safety and efficacy of intraoperative controlled delivery by biodegradable polymers of chemotherapy for recurrent gliomas. The Polymer-Brain Tumor Treatment Group. *Lancet* 345:1008-1012.
- Britton JW, Cascino GD, Sharbrough FW, Kelly PJ. 1994. Low-grade glial neoplasms and intractable partial epilepsy: efficacy of surgical treatment. *Epilepsia* 35:1130-1135.
- Cascino GD. 1990. Epilepsy and brain tumors: implications for treatment. *Epilepsia* 31[suppl 3]:S37-S44.
- Cascino TL. 1993. Neurologic complications of systemic cancer. *Med Clin North Am* 77:256-278.
- Claudo-Lacroix C, Lapresle J. 1985. [Pseudo-tumoral form of delayed radionecrosis of the brain]. *Ann Med Interne (Paris)* 136:137-141.
- Cicogna R, Bonomi FG, Curnis A, et al. 1993. Parapharyngeal space lesions syncope-syndrome. A newly proposed reflexogenic cardiovascular syndrome. *Eur Heart J* 14:1476-1483.
- Cohen N, Strauss G, Lew R, Silver D, Recht L. 1988. Should prophylactic anticonvulsants be administered to patients with newly diagnosed brain metastases? A retrospective analysis. *J Clin Oncol* 6:1621-1624.
- Collins RC, Al-Mondhiry H, Chernik NL, Posner JB. 1975. Neurologic manifestations of intravascular coagulation in patients with cancer. A clinicopathologic analysis of 12 cases. *Neurology* 25:795-806.
- Daggett P, Nabarro J. 1984. Neurological aspects of insulinomas. *Postgrad Med J* 60:577-581.
- Dalmau J, Graus F, Rosenblum MK, Posner JB. 1992. Anti-Hu-associated paraneoplastic encephalomyelitis/sensory neuronopathy. A clinical study of 71 patients. *Medicine (Baltimore)* 71:59-72.
- Delattre JY, Safai B, Posner JB. 1988. Erythema multiforme and Stevens-Johnson syndrome in patients receiving cranial irradiation and phenytoin. *Neurology* 38:194-198.
- DeMonaco HJ, Lawless LM. 1983. Variability of phenytoin protein binding in epileptic patients. *Arch Neurol* 40:481-483.
- de Toffol B, Uchuya M, Michalak S, Corcia P, Hommet C, Autret A. 1997. [Paraneoplastic encephalomyeloneuritis with anti-Hu antibodies and cancer of the rectum]. *Rev Neurol (Paris)* 153:135-137.
- de Waard DE, Verhorst PM, Visser CA. 1996. Exercise-induced syncope as late consequence of radiotherapy. *Int J Cardiol* 13:289-291.
- Dierckx RA, Michotte A, Schmedding E, Ebinger G, Degeeter T, van Camp B. 1985. Unilateral seizures in a patient with hairy cell leukemia treated with interferon. *Clin Neurol Neurosurg* 87:209-212.
- Drislane FW. 1994. Nonconvulsive status epilepticus in patients with cancer. *Clin Neurol Neurosurg* 96:314-318.
- Dykman TR, Montgomery EB Jr, Gerstenberger PD, Zeiger HE, Clutter WE, Cryer PE. 1981. Glossopharyngeal neuralgia with syncope secondary to tumor. Treatment and pathophysiology. *Am J Med* 71:165-170.
- Feun LG, Savaraj N, Lee YY, et al. 1991. A pilot clinical and pharmacokinetic study of intracarotid cisplatin and bleomycin. *Sel Cancer Ther* 7:29-36.
- Fischer HW. 1980. Occurrence of seizures during cranial computed tomography. *Radiology* 137:563-564.
- Fitzsimmons WE, Ghalie R, Kaizer H. 1990. The effect of hepatic enzyme inducers on busulfan neurotoxicity and myelotoxicity. *Cancer Chemother Pharmacol* 27:226-228.
- Flowers A, Levin VA. 1993. Management of brain metastases from breast carcinoma. *Oncology (Huntingt)* 7:21-26.
- Franck G, Sadot B, Salmon E, et al. 1987. [Paraneoplastic limbic encephalopathy, inappropriate ADH secretion and recurrent subclinical epileptic seizures. Clinical, anatomopathological and metabolic correlations by positron emission tomography]. *Rev Neurol (Paris)* 143:657-669.
- Fuse-Nagase Y, Suwa K, Nagao Y. 1997. Partial seizures associated with cisplatin administration: a case report. *Clin Electroencephalogr* 28:55-56.
- Ganapathi R, Hercberg A, Grabowski D, Ford J. 1993. Selective enhancement of vincristine cytotoxicity in multidrug-resistant tumor cells by dilantin. *Cancer Res* 53:3262-3265.
- Gattis WA, May DB. 1996. Possible interaction involving phenytoin, dexamethasone and antineoplastic agents: a case report and review. *Ann Pharmacother* 30:520-526.
- Genvesse I, Dietzmann A, Massenkeil G, Spath-Schwalbe E, Possinger K. 1999. Subacute encephalopathy after combination chemotherapy including moderate-dose methotrexate in a patient with gastric cancer. *Anticancer Drugs* 10:293-294.
- Ghany AM, Tutschka PJ, McGhee RB Jr, et al. 1991. Cyclosporine-associated seizures in bone marrow transplant recipients given busulfan and cyclophosphamide preparative therapy. *Transplantation* 52:310-315.
- Ghosh C, Lazarus HM, Hewlett JS, Creger RJ. 1992. Fluctuation of serum phenytoin concentrations during autologous bone marrow transplant for primary central nervous system tumors. *J Neurooncol* 12:25-32.
- Gieron MA, Barak LS, Estrada J. 1988. Severe encephalopathy associated with ifosfamide administration in two children with metastatic tumors. *J Neurooncol* 6:29-30.
- Goetting MG, Thirman MJ. 1985. Neurotoxicity of meperidine. *Ann Emerg Med* 14:1007-1009.
- Graus F, Rogers LR, Posner JB. 1985. Cerebrovascular complications in patients with cancer. *Cancer* 64:16-35.
- Grossman SA, Hochberg F, Fisher J, et al. 1998. Increased 9-aminocamptothecin dose requirements in patients on anticonvulsants. NABTT CNS Consortium. The New Approaches to Brain Tumor Therapy. *Cancer Chemother Pharmacol* 42:118-126.
- Grossman SA, Sheidler VR, Gilbert MR. 1989. Decreased phenytoin levels in patients receiving chemotherapy. *Am J Med* 87:505-510.

- Gross-Tsur V, Manor O, van der MJ, Meere J, Joseph A, Shalev RS. 1997. Epilepsy and attention deficit hyperactivity disorder: is methylphenidate safe and effective? *J Pediatr* 130:670-674.
- Hassan M, Oberg G, Bjorkholm M, Wallin I, Lindgren M. 1993. Influence of prophylactic anticonvulsant therapy on high-dose busulfan kinetics. *Cancer Chemother Pharmacol* 33:181-186.
- Hazard J, Simon D, Perlemuter L, et al. 1985. [Insulinoma: diagnostic elements. 13 cases]. *Presse Med (Paris)* 14:1775-1778.
- Hoefnagels WA, Padberg GW, Overweg J, Roos RA, van Dijk JG, Kamphuisen HA. 1991. Syncope or seizure? The diagnostic value of the EEG and hyperventilation test in transient loss of consciousness. *J Neurol Neurosurg Psychiatry* 54:953-956.
- Hook CC, Kimmel DW, Kvols LK, et al. 1992. Multifocal inflammatory leukoencephalopathy with 5-fluorouracil and levamisole. *Ann Neurol* 31:262-267.
- Hurwitz RL, Mahoney DH Jr, Armstrong DL, Browder TM. 1988. Reversible encephalopathy and seizures as a result of conventional vincristine administration. *Med Pediatr Oncol* 16:216-219.
- Jain KK. 1993. Investigation and management of loss of efficacy of an antiepileptic medication using carbamazepine as an example. *J R Soc Med* 86:133-136.
- Kaiko RF, Foley KM, Grabinski PY, et al. 1983. Central nervous system excitatory effects of meperidine in cancer patients. *Ann Neurol* 13:180-185.
- Kapoor WN. 1991. Diagnostic evaluation of syncope. *Am J Med* 90:91-106.
- Kapoor WN. 1992. Evaluation and management of the patient with syncope. *JAMA* 268:2553-2560.
- Karp BI, Yang JC, Khorsand M, et al. 1996. Multiple cerebral lesions complicating therapy with interleukin-2. *Neurology* 47:417-424.
- Kramer ED, Packer RJ, Ginsberg J, et al. 1997. Acute neurologic dysfunction associated with high-dose chemotherapy and autologous bone marrow rescue for primary malignant brain tumors. *Pediatr Neurosurg* 27:230-237.
- Kronenberg MF, Laimer I, Rifici C, et al. 1998. Epileptic seizures associated with intracerebroventricular and intrathecal morphine bolus. *Pain* 75:383-387.
- Lackner TE. 1991. Interaction of dexamethasone with phenytoin. *Pharmacotherapy* 11:344-347.
- Lee AC, Wong K W, Fong K W, So K T. 1997. Intrathecal methotrexate overdose. *Acta Paediatr* 86:434-437.
- Lehmann DF, Hurteau TE, Newman N, Coyle TE. 1997. Anticonvulsant usage is associated with an increased risk of procarbazine hypersensitivity reactions in patients with brain tumors. *Clin Pharmacol Ther* 62:225-229.
- Lieschke GJ, Cebon J, Morstyn G. 1989. Characterization of the clinical effects after the first dose of bacterially synthesized recombinant human granulocyte-macrophage colony-stimulating factor. *Blood* 74:2634-2643.
- Lim SH, So NK, Luders H, Morris HH, Turnbull J. 1991. Etiologic factors for unitemporal vs bitemporal epileptiform discharges. *Arch Neurol* 48:1225-1228.
- Lordo CD, Stroude EC, Del Maestro RF. 1987. The effects of diphenylhydantoin on murine astrocytoma radiosensitivity. *J Neurooncol* 5:339-350.
- Lovblad K, Kelkar F, Ozdoba C, Ramelli G, Remonda L, Schroth G. 1998. Pure methotrexate encephalopathy presenting with seizures: CT and MRI features. *Pediatr Radiol* 28:86-91.
- Manolis AS, Linzer M, Salem D, Estes NA 3rd. 1990. Syncope: current diagnostic evaluation and management. *Ann Intern Med* 112:850-863.
- Mary-Rabine L, Waleffe A, Kulbertus HE. 1980. Severe conduction disturbances and ventricular arrhythmias complicating mediastinal irradiation for Hodgkin's disease: a case report. *Pacing Clin Electrophysiol* 3:612-617.
- McDonald GA, Dubose TD Jr. 1993. Hyponatremia in the cancer patient. *Oncology (Huntingt)* 7:55-64.
- Meisel SB, Welford PK. 1992. Seizures associated with high-dose intravenous morphine containing sodium bisulfite preservative. *Ann Pharmacother* 26:1515-1517.
- Menendez LR, Bacon W, Kempf RA, Moore TM. 1990. Fat embolism syndrome complicating intraarterial chemotherapy with cis-platinum. *Clin Orthop* 254:294-297.
- Meyers CA, Obbens EA, Scheibel RS, Moser RP. 1991. Neurotoxicity of intraventricularly administered alpha-interferon for leptomeningeal disease. *Cancer* 68:88-92.
- Meyers CA, Weitzner MA, Valentine AD, Levin VA. 1998. Methylphenidate therapy improves cognition, mood, and function of brain tumor patients. *J Clin Oncol* 16:2522-2527.
- Neef C, de Voogd-van der Straaten I. 1988. An interaction between cytostatic and anticonvulsant drugs. *Clin Pharmacol Ther* 43:372-375.
- Newell EA, Dahlborg SA. 1987. Chemotherapy administered in conjunction with osmotic blood-brain barrier modification in patients with brain metastases. *J Neurooncol* 4:195-207.
- Nieto Y, Cagnoni PJ, Bearman SL, et al. 1999. Acute encephalopathy: a new toxicity associated with high-dose paclitaxel. *Clin Cancer Res* 5:501-506.
- Patronas NJ, Argyropoulou M. 1992. Intravascular thrombosis as a possible cause of transient cortical brain lesions: CT and MRI. *J Comput Assist Tomogr* 16:849-855.
- Perry JR, Warner E. 1996. Transient encephalopathy after paclitaxel (Taxol) infusion. *Neurology* 46:1596-1599.
- Pihko H, Tyni T, Virkola K, et al. 1993. Transient iosemic cerebral lesions during induction chemotherapy for acute lymphoblastic leukemia. *J Pediatr* 123:718-724.
- Plum F, Posner JB. 1982. *The Diagnosis of Stupor and Coma*, 3rd ed. Philadelphia: FA Davis, pp 210-211.
- Priest JR, Ramsay NK, Latchaw RE, et al. 1980. Thrombotic and hemorrhagic strokes complicating early therapy for childhood acute lymphoblastic leukemia. *Cancer* 46:1548-1554.
- Pruitt AA. 1991. Central nervous system infections in cancer patients. *Neurol Clin* 9:867-888.
- Quinn CT, Griener JC, Bottiglieri K, Hyland K, Farrow A, Kamen BA. 1997. Elevation of homocysteine and excitatory amino acid neurotransmitters in the CSF of children who receive methotrexate for the treatment of cancer. *J Clin Oncol* 15:2800-2806.
- Resar LM, Phillips PC, Kastan MB, Leventhal BG, Bowman PW, Civin CI. 1993. Acute neurotoxicity after intrathecal cytosine arabinoside in two adolescents with acute lymphoblastic leukemia of B-cell type. *Cancer* 71:117-123.
- Richardson GE. 1995. Hyponatremia of malignancy. *Crit Rev Oncol Hematol* 18:129-135.

- Rider WD. 1963. Radiation damage to the brain—a new syndrome. *J Can Assoc Radiol* 14:67–69.
- Ritch PS. 1988. Cis-dichlorodiammineplatinum II-induced syndrome of inappropriate secretion of antidiuretic hormone. *Cancer* 61:448–450.
- Rogers LR, Morris HH, Lupica K. 1993. Effect of cranial irradiation on seizure frequency in adults with low-grade astrocytoma and medically intractable epilepsy. *Neurology* 43:1599–1601.
- Rosen P, Armstrong D. 1973. Nonbacterial thrombotic endocarditis in patients with malignant aneoplastic diseases. *Am J Med* 54:23–29.
- Rosner D, Nemoto T, Lane WW. 1986. Chemotherapy induces regression of brain metastases in breast carcinoma. *Cancer* 58:832–839.
- Salloum E, Khan KK, Cooper DL. 1997. Chlorambucil-induced seizures. *Cancer* 79:1009–1013.
- Sasaki M, Ichiya Y, Kuwabara Y, et al. 1996. Hyperperfusion and hypermetabolism in brain radiation necrosis with epileptic activity. *J Nucl Med* 37:1174–1176.
- Schliamser SE, Cars O, Norrby SR. 1991. Neurotoxicity of beta-lactam antibiotics: predisposing factors and pathogenesis. *J Antimicrob Chemother* 27:405–425.
- Schroeder H, Ostergaard JR. 1994. Interference of high-dose methotrexate in the metabolism of valproate? *Pediatr Hematol Oncol* 11:445–449.
- Shapiro MH, Ruiz-Ramon P, Fainman C, Ziegler MG. 1996. Light-headedness and defective cardiovascular reflexes after neck radiotherapy. *Biol Press Monit* 1:81–85.
- Shehata N, Pater A, Tang SC. 1999. Prolonged severe 5-fluorouracil-associated neurotoxicity in a patient with dihydropyrimidine dehydrogenase deficiency. *Cancer Invest* 17:201–205.
- Silverman DA, Chapron DJ. 1995. Lymphopenic effect of carbamazepine in a patient with chronic lymphocytic leukemia. *Ann Pharmacother* 29:865–867.
- Smith DF, Hutton JL, Sandemann D, et al. 1991. The prognosis of primary intracerebral tumours presenting with epilepsy: the outcome of medical and surgical management. *J Neurol Neurosurg Psychiatry* 54:915–920.
- Smith GA, Damon LE, Rugo HS, Ries CA, Linker CA. 1997. High-dose cytarabine dose modification reduces the incidence of neurotoxicity in patients with renal insufficiency. *J Clin Oncol* 15:833–839.
- Snider S, Bashir R, Bierman P. 1994. Neurologic complications after high-dose chemotherapy and autologous bone marrow transplantation for Hodgkin's disease. *Neurology* 44:681–684.
- Spencer MD. 1998. Leukoencephalopathy after CNS prophylaxis for acute lymphoblastic leukaemia. *Pediatr Rehabil* 2:33–39.
- Stein DA, Chamberlain MC. 1991. Evaluation and management of seizures in the patient with cancer. *Oncology (Huntingt)* 5:33–39.
- Stewart DJ, Belanger JM, Grahovac Z, et al. 1992. Phase I study of intracarotid administration of carboplatin. *Neurosurgery* 30:512–516.
- Szeto HH, Inturrisi CE, Houde R, Saal S, Cheigh J, Reidenberg MM. 1977. Accumulation of normeperidine, an active metabolite of meperidine, in patients with renal failure of cancer. *Ann Intern Med* 86:738–741.
- Tahsildar HI, Remler BF, Creger RJ, et al. 1996. Delayed, transient encephalopathy after marrow transplantation: case reports and MRI findings in four patients. *J Neurooncol* 27:241–250.
- Trillet V, Biron P. 1989. [Brain metastases: diagnostic and therapeutic strategy]. *Presse Med* 18:1471–1475.
- Vanhees SL, Raridaens K, Vansteenkiste JF. 2000. Syndrome of inappropriate antidiuretic hormone associated with chemotherapy-induced tumour lysis in small-cell lung cancer. Case report and literature review. *Ann Oncol* 11:1061–1065.
- Walton GD, Hon JK, Mulpur TG. 1997. Ofloxacin-induced seizure. *Ann Pharmacother* 31:1475–1477.
- Wang CH, Ng SH. 1995. Syncope as the initial presentation of nasopharyngeal carcinoma. *J Neurooncol* 25:73–75.
- Wasserstrom WR, Glass JP, Posner JB. 1982. Diagnosis and treatment of leptomeningeal metastases from solid tumors: experience with 90 patients. *Cancer* 49:759–772.
- Weiss HD, Walker MD, Wiernik PH. 1974. Neurotoxicity of commonly used antineoplastic agents (first of two parts). *N Engl J Med* 291:75–81.
- Weitzner MA, Meyers CA, Valentine AD. 1995. Methylphenidate in the treatment of neurobehavioral slowing associated with cancer and cancer treatment. *J Neuropsychiatry Clin Neurosci* 7:347–350.
- Werner-Wasik M, Rudoler S, Preston PE, et al. 1999. Immediate side effects of radiotherapy and radiosurgery. *Int J Radiat Oncol Biol Phys* 43:299–304.
- Wroblewski BA, Leary JM, Phelan AM, et al. 1992. Methylphenidate and seizure frequency in brain injured patients with seizure disorders. *J Clin Psychiatry* 53:86–89.
- Zamboni WC, Gajjar AJ, Heideman RL, et al. 1998. Phenytoin alters disposition of topotecan and N-desmethyl topotecan in a patient with medulloblastoma. *Clin Cancer Res* 4:783–789.