

Leptomeningeal Metastases

LISA BOMGAARS, MARC C. CHAMBERLAIN,
DAVID G. POPLACK, AND SUSAN M. BLANEY

The leptomeninges are anatomically defined as the pia mater and the arachnoid, tissue envelopes that encase the brain and the spinal cord. Invasion of the leptomeninges or the cerebrospinal fluid (CSF) by cancer is called *leptomeningeal metastasis* or *neoplastic meningitis*. These are general terms that encompass

1. Carcinomatous meningitis (metastases caused by carcinoma such as lung and breast)
2. Meningeal gliomatosis (dissemination of CSF caused by malignant glial tumors)
3. Leptomeningeal metastases secondary to other underlying solid tumors (e.g., rhabdomyosarcoma, neuroblastoma, medulloblastoma, other primitive neuroectodermal tumors)
4. Lymphomatous meningitis (metastases caused by lymphoma)
5. Leukemic meningitis (metastases caused by leukemia) (Chamberlain, 1992; Grossman and Moynihan, 1991; Kaplan et al., 1990; Little et al., 1974; Olson et al., 1974; Packer et al., 1985; Shapiro et al., 1977; Theodore and Gendelman, 1981; Wasserstrom et al., 1982; Yung et al., 1980).

Leptomeningeal metastases are an increasingly common complication, estimated to occur in approximately 5% of all patients with cancer (Chamberlain, 1992; Grossman and Moynihan, 1991; Kaplan et al., 1990). The increasing incidence of leptomeningeal metastases in patients with solid tumors appears to be due to the increasing incidence of cancer in the general population and to the fact that cancer patients are living longer

because of more effective treatment of their systemic cancer; the latter appears to lead to a paradoxical increase in central nervous system (CNS) metastases.

Leptomeningeal metastases resulting from solid tumors most often present in patients with advanced systemic or primary CNS cancer, and these metastases therefore coexist with active systemic bulk CNS parenchymal disease (Grossman and Moynihan, 1991; Kaplan et al., 1990; Posner and Chernik, 1978; Wasserstrom et al., 1982). In contrast, leukemic and lymphomatous meningitides frequently represent the first site of tumor recurrence without evidence of systemic disease (Kaplan et al., 1990). In approximately 5% to 10% of patients, leptomeningeal metastases are the initial presentation of cancer. In such cases, disease staging must be initiated to define the primary tumor and its pattern of metastases (Chamberlain, 1992; Grossman and Moynihan, 1991). This chapter discusses leptomeningeal metastases, with a primary emphasis on leptomeningeal metastases from solid tumors. It includes a review of the diverse clinical presentation of this disease entity, provides current information on diagnosis and management, and discusses new therapeutic options that are in preclinical or early clinical stages of development.

LEPTOMENINGEAL METASTASES BY CANCER TYPE

Reported histologic variability between series in organ-site tumors that lead to leptomeningeal metasta-

sis reflects differences in hospital referral patterns. Solid tumors are disproportionately represented because of their overall greater prevalence and, in some series, because disseminated primary brain tumors and leukemic and lymphomatous meningitis are excluded. Of the solid tumors causing leptomeningeal metastases, those from breast occur in 30% of patients (range, 22% to 64%); lung in 16% (range, 10% to 26%); malignant melanoma in 11% (range, 7% to 15%); and the gastrointestinal tract in 6% (range, 4% to 14%). Carcinomas of an unknown primary origin constitute 1% to 7% of all cases of leptomeningeal metastases in most clinical series (Little et al., 1974; Theodore and Gendelman, 1981; Wasserstrom et al., 1982). The frequency of occurrence of primary brain tumors causing leptomeningeal metastases is from 10% to 32% depending on histology, patient age, and referral patterns (Chamberlain and Corey-Bloom, 1991; Kaplan et al., 1990; Shapiro et al., 1977; Wasserstrom et al., 1982). Lymphomatous meningitis associated with non-Hodgkin's lymphoma in patients with the acquired immunodeficiency syndrome (AIDS) is also an increasingly common cause of leptomeningeal metastases. This has been reported to occur in approximately 20% of patients with AIDS who have systemic non-Hodgkin's lymphoma and in 25% of those who have primary lymphoma of the CNS (Chamberlain and Kormanik, 1997; Chamberlain and Dirr, 1993).

Autopsy studies demonstrate an even higher incidence of leptomeningeal metastases than that established through clinical studies of patients with known leptomeningeal metastases. In the Memorial Sloan-Kettering Cancer Center experience, 8% of 2375 patients with cancer demonstrated leptomeningeal metastases at autopsy (Posner and Chernik, 1978). Similarly, in a National Institutes of Health study of patients with small cell lung cancer, 11% manifested leptomeningeal metastases while alive compared with a 25% incidence found at postmortem examination (Rosen et al., 1982).

CLINICAL PRESENTATIONS

Unlike other cancers that affect the CNS, the clinical signs and symptoms of leptomeningeal metastases are highly variable because they affect all levels of the neuraxis (Chamberlain and Corey-Bloom, 1991; Kaplan et al., 1990; Little et al., 1974; Olson et al., 1974;

Theodore and Gendelman, 1981; Wasserstrom et al., 1982). The degree of clinical pleomorphism of leptomeningeal metastases is problematic as clinical recognition may be delayed because of unfamiliarity with the wide spectrum of associated signs and symptoms. As shown in Table 16-1, these signs and symptoms are traditionally referable to three broad domains encompassing the neuraxis, including the cerebral hemispheres, cranial nerves, spinal cord, and exiting nerve roots. Site-specific symptoms and signs are summarized in Table 16-2.

Symptoms referable to the cerebral hemispheres include, in decreasing order of frequency, headache, mental status change, nausea and vomiting, and hemibody weakness and seizures. Headache, the most common symptom of cerebral dysfunction caused by leptomeningeal metastases, may be the only symptom and usually involves the entire head or the occiput and the neck. Frequently, headache, like nausea and vomiting, is a consequence of raised intracranial pressure resulting from either obstructive or communicating hydrocephalus. Hydrocephalus is a common consequence of leptomeningeal metastases that results from an intraventricular tumor or from base-of-the-brain leptomeningeal infiltration (Kokkoris, 1983). Mental status changes range from slight slowing of thought processes (so-called *oligophrenia*) to depressed levels of consciousness. In late stages of leptomeningeal metastases, patients often manifest profound changes in mental status, referred to as *carcinomatous encephalopathy*, a process that is immediately progressive and contributes to death from leptomeningeal metastases. Seizures and hemibody weakness are uncommon manifestations of leptomeningeal metastases and often coexist with bulky intraparenchymal or subarachnoid tumor.

Table 16-1. Mean Frequency of Initial Symptoms and Signs of Leptomeningeal Metastasis

	Symptom (%)	Signs (%)
Cerebral hemisphere	46	41
Cranial nerves	37	58
Spinal cord and roots	50	69
Multiple site	32	47

Source: Data are from Chamberlain and Corey-Bloom (1991), Kaplan et al. (1990), Little et al. (1974), Olson et al. (1974); Theodore and Gendelman (1981), and Wasserstrom et al. (1982).

Table 16–2. Symptoms and Signs of Leptomeningeal Disease by Site and Decreasing Order of Frequency

	<i>Symptom</i>	<i>Signs</i>
Cerebral hemisphere	Headache	Mental status change
	Mental status change	Seizures
	Nausea/vomiting	Papilledema
	Hemibody weakness	Focal weakness
	Seizures	Hemiparesis
Cranial nerves	Diplopia	Ophthalmoplegia (VI,III,IV)
	Hearing loss	Facial weakness (VII)
	Facial numbness	Decreased hearing (VIII)
	Decreased vision	Facial neuropathy (V) Hypoglossal weakness (XII)
Spinal cord and roots	Limb weakness	Extremity weakness
	Pain	Dermatomal/segmental sensory loss
	Gait instability	Deep tendon reflex abnormality
	Bladder dysfunction	Nuchal rigidity (meningismus)
	Bowel dysfunction	Ataxia of gait Pain on straight leg raising

Signs referable to the cerebral hemispheres include, in decreasing order of frequency, mental status changes, seizures, papilledema, and hemiparesis. Mental status changes may manifest as dementia; in general, these signs are resistant to treatment. Papilledema, like headache, nausea, and vomiting, reflects raised intracranial pressure and, usually, hydrocephalus. Signs and symptoms of raised intracranial pressure caused by leptomeningeal metastases may transiently respond to combined treatment with whole-brain irradiation and intrathecal chemotherapy (Chamberlain, 1992; Chamberlain and Corey-Bloom, 1991).

Symptoms of cranial nerve involvement include, in decreasing order of frequency, double vision, hearing loss, facial numbness, and loss of vision. The most frequent signs of cranial nerve involvement include ophthalmoplegia (affecting, in order, cranial nerves VI, III, and IV); facial weakness (affecting cranial nerve VII); diminished hearing (affecting cranial nerve VIII); trigeminal neuropathy (affecting cranial nerve V); and hypoglossal weakness (affecting cranial nerve XII). A disturbance in eye movement with resultant diplopia or oscillopsia is frequently an early, and often isolated, sign of leptomeningeal metastases. Patients with cancer manifesting new onset of lateral rectus palsy (affecting cranial nerve VI) should be evaluated for possible leptomeningeal metastases following a negative neuroradiographic evaluation for

intracranial tumor. Occasionally patients present with a disturbance of hearing (either unilateral or bilateral), facial weakness, or decreased facial sensation in a trigeminal distribution (trigeminal motor dysfunction, i.e., trouble opening or closing the jaw), although these findings occur more often in cases of advanced leptomeningeal metastases in which multiple cranial neuropathies coexist. As with altered mental status, multiple cranial nerve dysfunction, especially with rapid temporal evolution, is a poor prognostic sign. In addition, focal deficits such as cranial neuropathies respond poorly, if at all, to either radiotherapy (whole brain or base of brain) or intrathecal drug therapy. Cranial nerve dysfunction appears to reflect the tumor's preferential involvement at the base of the brain with the tumor infiltrating basal CSF compartments (Kokkoris, 1983).

Spinal cord and exiting root symptoms include those resulting from involvement of the spinal cord (cervical, thoracic, or lumbar); the conus medullaris (the caudal-most portion of the spinal cord proper); the cauda equina (nerve roots contained within the lumbosacral dural sac); the exiting nerve roots (contained within dural sleeves); and the spinal meninges. The most common of these symptoms are limb weakness or numbness, pain (i.e., meningismus), gait instability, and bladder and bowel dysfunction. Limb weakness usually manifests either as a polyradiculoneuropathy (involvement of multiple exiting nerve

roots or cauda equina), in which lower motor neuron findings predominate (decreased limb tone, diminished or absent deep tendon reflexes, and dermatomal or root-referable sensory loss), or as a myelopathy (as with spinal cord or conus medullaris dysfunction), in which upper motor neuron findings predominate (increased limb tone, exaggerated deep tendon reflexes, extensor planar response, and segmental or fixed-level sensory loss). Bladder or bowel dysfunction in isolation is never a finding of leptomeningeal metastases but rather occurs early with spinal cord or conus medullaris dysfunction or late with cauda equina dysfunction in conjunction with other signs of neurologic disturbance. In a patient with cancer and spinal cord dysfunction, if spinal cord compression resulting from an epidural mass is ruled out by computed tomography (CT) myelography or contrast-enhanced magnetic resonance imaging (MRI) of the spine, then leptomeningeal metastases should be strongly considered. Pain, like epidural spinal cord compression, may be localized (e.g., neck, interscapular, or lumbar); radicular (conforming to a nerve root distribution); or referred (distant pain such as isolated knee pain). Gait instability is a common disorder of the spinal cord in patients with leptomeningeal metastases and often heralds tumor progression.

Common signs referable to the spine in patients who have leptomeningeal metastases include extremity weakness (lower or upper motor neuron pattern), dermatomal or segmental sensory loss, exaggerated or diminished to absent deep tendon reflexes, nuchal rigidity (meningismus), ataxia, and pain on raising a straightened leg. Spinal cord dysfunction is dominated by focal neurologic deficits that respond poorly to treatment, including limited-field spine irradiation or intrathecal fluid chemotherapy, whereas pain symptoms usually respond to treatment (Chamberlain, 1992; Kaplan et al., 1990).

With progression of leptomeningeal metastases, new signs and symptoms appear and pre-existing findings worsen. Patients with underlying solid tumors are more likely to present with spinal or radicular symptoms, whereas patients with hematologic malignancies more often present with cranial nerve dysfunction. Multifocal neurologic symptoms may be seen in two-thirds of patients and may be a sign of progressive leptomeningeal disease (Van Oostenbrugge and Twijnstra, 1999). Rapid progression of leptomeningeal metastases involving one or multiple CNS regions is invariably a poor prognostic sign.

APPROACH TO DIAGNOSIS

The diagnosis of leptomeningeal metastases is made by correlating physical signs and symptoms with laboratory findings and neuroimaging studies. In the past, the presence of malignant cells in the CSF was a prerequisite for diagnosing leptomeningeal disease. However, discrepancies may exist between clinical signs and symptoms and results of CSF examination(s). Improvements in neuroimaging technology, particularly the widespread availability of MRI, have increased the feasibility of establishing a diagnosis of leptomeningeal metastases using imaging techniques. In some instances the presence of typical clinical features coupled with appropriate neuroimaging abnormalities are adequate for making the diagnosis of leptomeningeal metastases (Freilich et al., 1995).

Cerebrospinal Fluid Examination

One of the most important diagnostic procedures for establishing the presence of leptomeningeal metastases is examination of the CSF (Table 16-3). Essential elements of the CSF laboratory evaluation include cell count and differential, cytology, and protein and glucose concentrations. In patients who have primary solid tumors, the finding of malignant cells in the CSF provides unequivocal evidence of leptomeningeal metastases. The initial lumbar puncture will show abnormalities in all but a minority of patients when opening pressure and CSF cell count, glucose protein levels and cytology are considered (Kaplan et al., 1990; Olson et al., 1974; Theodore and Gendelman, 1981; Wasserstrom et al., 1982). In approximately 50% of patients with leptomeningeal metastases, the CSF opening pressure will be elevated. Similarly, a majority of patients with leptomeningeal metastases have elevated protein levels, and increased CSF cell counts. A depressed CSF glucose level (so-called hypoglycorrhachia) is seen in a minority (<30%) of patients with leptomeningeal metastases. However, alone, such abnormal findings in the CSF are non-specific and may be present in various neurologic disorders.

Until recently, the diagnosis of leptomeningeal metastases could not be made without finding malignant cells in the CSF. However, improvements in neuroimaging technology have increased the feasibility of establishing a radiographic diagnosis of leptomeningeal metastases. In a recent review, in 106

Table 16-3. Mean Findings at Lumbar Examination of the Cerebrospinal Fluid

<i>Finding</i>	<i>Initial Examination (%)</i>	<i>All Examinations (%)</i>
Pressure >150 mm of H ₂ O	46	66
WBC >4/mm ³	59	76
Protein >50 mg/dl	78	86
Glucose <40 mg/dl	43	60
Positive cytology	61	92

WBC, white blood cell count.

Source: Data are from Kaplan et al. (1990), Olson et al. (1974), Theodore and Gendelman (1981), and Wasserstrom et al. (1982).

consecutively diagnosed pediatric patients with medulloblastoma, spinal MRI and CSF cytology were evaluated for the presence of leptomeningeal metastases. Of these patients, 8.5% had positive MRI findings with negative CSF cytology; and 11.3% had positive CSF cytology with negative MRIs. Either CSF cytology or spinal MRI alone would have missed leptomeningeal disease in as many as 14% to 18% (Fouladi et al., 1999). Therefore, patients with a clinical syndrome or neuroradiographic findings compatible with a diagnosis of leptomeningeal metastases should be treated in a similar fashion to those patients with cytologically proven leptomeningeal metastases (Chamberlain, 1992).

Several series have demonstrated that, in some cases, serial CSF sampling via lumbar puncture or sampling from alternate sites (e.g., cisternal or ventricular) is required to detect malignant cells. The experience of Wasserstrom et al. (1982) in 90 patients with solid tumor leptomeningeal metastases revealed positive cytology in 55% of them after an initial lumbar puncture, increasing to 80% after a second lumbar puncture. Each subsequent lumbar puncture yielded positive cytology in approximately an additional 2% of patients per lumbar examination of CSF. An additional 5% of patients showed positive cytology only after cisternal or ventricular examination of CSF; 10% of patients showed persistently negative cytology for malignant cells in CSF regardless of site or number of examinations.

In a small series of patients with leptomeningeal metastases, Rogers et al. (1992) found that nearly 20% with leptomeningeal metastases demonstrated positive cytology only on cisternal examination of the CSF. In another study of 63 cases of cytologically confirmed leptomeningeal metastases, including solid tu-

mors, leukemia, and lymphoma, Kaplan et al. (1990) reported positive cytologic findings in 71% of patients on the first lumbar puncture and in 21% on the second lumbar puncture; only 8% required more than two lumbar punctures to demonstrate positive cytology. In addition, Kaplan et al. (1990) emphasized that CSF cell count was a poor predictor of positive cytology because cell counts were normal in 29% of cases in which lumbar punctures yielded positive cytologic results.

Similarly, in a small number of patients with leptomeningeal metastases, Murray et al. (1983) emphasized marked variations in CSF composition, including cytologic specimens from different levels of the neuraxis (lumbar, cisternal, and ventricular CSF compartments) in the absence of an epidural block to the CSF flow. Harrison et al. (1998) also suggested that lumbar CSF samples correlate better with imaging findings when compared with ventricular CSF samples. Furthermore, in adults with leptomeningeal metastases, the initial CSF cytology was composed of malignant cells more often in patients with an underlying solid tumor versus those with hematologic malignancies that were predominantly non-Hodgkin's lymphomas (73% versus 53%) (Van Oostenbrugge and Twijnstra, 1999).

Results from these series suggest a practical approach to the examination of CSF in patients with solid tumors and clinically suspected leptomeningeal metastases: After two tumor-negative cytologic samples from lumbar puncture and negative neuroimaging studies (gadolinium-enhanced MRIs of the brain and spinal cord), examination of the CSF from alternate sites (e.g., cisternal or ventricular) should be considered. A minority of patients will have clinical presentations compatible with leptomeningeal metas-

tases and negative evaluations for malignant cells from CSF along with negative neuroradiographic studies; in these patients treatment may be initiated, assuming there is a known history of an underlying malignancy and other diagnostic possibilities have been excluded (e.g., epidural spinal cord compression, paraneoplastic disorders, and toxic or metabolic complications of cancer therapy).

In patients with leptomeningeal metastases, measurement of CSF tumor markers such as carcinoembryonic antigen and α -glucuronidase may assist in diagnosis or evaluation after treatment (Chamberlain, 1998b; Schold et al., 1980; Twijnstra et al., 1989). Other biochemical markers for leptomeningeal metastases include α -fetoprotein, the β -subunit of human chronic gonadotropin, α_2 -microglobulin, glucose-phosphate isomerase, immunoglobulin indices (either IgG or IgM), and oligoclonal bands (Ernerudh et al., 1987; Klee et al., 1986; Malkin and Posner, 1987; Newton et al., 1991; Schipper et al., 1988). Tumor markers should be simultaneously obtained from serum and CSF to determine if an elevation in a CSF marker is a result of passive diffusion or secondary to leptomeningeal disease (DeAngelis, 1998).

In addition to the specific biochemical markers noted above, other useful adjuncts to CSF cytology include flow cytometry, measurement of immunophenotype, fluorescence in situ hybridization, chromosomal analysis, and immunohistochemical studies. The underlying diagnostic utility of such studies largely depends on the underlying systemic malignancy. For example, lymphocytes in the CSF may not be readily identifiable as malignant by the cytopathologist, but a demonstration of monoclonality (lambda or kappa light chain-directed monoclonal antibody analysis), B-cell lineage, or a specific chromosomal abnormality may differentiate leukemic or lymphomatous meningitis from a normal or reactive T-cell population (Cibas et al., 1987; Coakham et al., 1984; Grossman and Moynihan, 1991; Recht, 1991; Walker, 1991). Glial fibrillary acidic protein histochemistry of CSF may also facilitate identification of malignant glial cells (Chamberlain, 1995a). Likewise, fluorescence in situ hybridization has been shown to be a feasible modality to aid in the diagnosis of leptomeningeal disease in breast cancer patients (Van Oostenbrugge et al., 1997).

Neuroradiographic Studies

Magnetic Resonance Imaging and Computed Tomography Scans

A variety of neuroradiographic studies may be helpful in establishing a diagnosis, defining the extent of disease (i.e., CNS staging), and following treatment response in patients who have leptomeningeal metastases. Abnormal neuroimaging is seen more commonly in patients with underlying solid malignancies than in those with underlying hematologic malignancies (Van Oostenbrugge and Twijnstra, 1999). As demonstrated by Chamberlain et al. (1990), gadolinium-enhanced imaging of the head and spine are the preferred neuroimaging studies for the diagnosis of leptomeningeal metastases, although contrast-enhanced CT studies may also demonstrate abnormalities. As shown in Table 16-4, gadolinium-enhanced MRI has both a higher specificity and a higher sensitivity than CT imaging.

Contrast-enhanced CT of the head reveals abnormalities in approximately 25% to 56% of patients with leptomeningeal metastases, including

1. Sulcal or cisternal enhancement
2. Ependymal and subependymal enhancement
3. Irregular tentorial enhancement
4. Cisternal or sulcal obliteration
5. Subarachnoid enhancing nodules
6. Intraventricular enhancing nodules
7. Communicating hydrocephalus

Table 16-4. Findings in Comparative MRI and CT Contrast-Enhanced Brain Imaging

<i>Finding</i>	<i>MRI Scan (%)</i>	<i>CT Scan (%)</i>
Parenchymal volume loss	93	93
Abnormal enhancement	71	29
Sulcal/dural	50	21
Cisternal	29	14
Tentorial	21	0
Ependymal	21	7
Nodules	43	36
Subarachnoid	36	29
Parenchymal	43	29
Hydrocephalus	7	7

Source: Adapted from Chamberlain et al. (1990).

In addition, as many as 60% of patients whose findings from contrast-enhanced CT suggest leptomeningeal metastases have coexistent parenchymal metastasis. All abnormalities detected on contrast-enhanced CT scans were detected through gadolinium-enhanced MRI, which also revealed additional lesions not otherwise seen. Despite the superiority of gadolinium-enhanced MRI, both modalities have a high incidence of false-negative results (30% for gadolinium-enhanced MRI and 58% for contrast-enhanced CT). Normal findings by either or both examinations do not exclude a diagnosis of leptomeningeal metastases. In the majority of patients with leptomeningeal metastases, gadolinium-enhanced MRI is also more useful than other imaging modalities in demonstrating bulky disease, a pattern of disease most responsive to radiotherapy. Kallmes et al. (1998) have suggested employing high-dose gadolinium-enhanced MRI to diagnose meningeal metastases when a strong clinical suspicion exists following a negative standard-dose gadolinium-enhanced MRI.

Kim et al. (1982) delineated the patterns seen in patients who had leptomeningeal metastases on CT myelography scans, including

1. Parallel longitudinal striations in the cauda equina caused by thickened nerve roots
2. Irregular intradural extramedullary filling defects with varying degrees of blockage resembling arachnoiditis
3. Multiple intradural nodular defects along nerve roots
4. Amputation of dural root sleeves
5. Focal enlargement of the spinal cord or conus
6. Intradural extramedullary blockage to contrast flow

Similar findings are noted on contrast-enhanced spinal MRI, which is superior in demonstrating intradural extramedullary nodules, focal spinal cord enlargement, clumping of nerve roots, and spinal cord pial enhancement, often termed "sugar coating" (Chamberlain, 1995b; Kramer et al., 1991; Lim et al., 1990; Sze et al., 1988). In a study by Chamberlain (1995a) that directly compared CT myelography with MR imaging of the spine, few discordant results were noted between these modalities. However, MRI is preferred because it is (1) comparable to CT myelography, (2) noninvasive, (3) has a low rate of procedure-related morbidity, and (4) is

associated with greater patient acceptance (Chamberlain, 1995a,b).

The optimal contrast-enhanced MRI examination of the spine for evaluating intradural extramedullary disease seen in patients with leptomeningeal metastases includes T₁-weighted sagittal scans taken before and after gadolinium administration, with T₁-weighted axial images reserved for regions of interest that either are detected by sagittal imaging or exist in regions with clinically suspect disease (i.e., the cauda equina) (Sze et al., 1988). It is important to note that MRI changes may be seen following lumbar puncture or a neurosurgical procedure and include meningeal reaction appearing as leptomeningeal enhancement, which may occur at the level of the lumbar roots and extend as far rostral as the cranium. Linear enhancement may persist for weeks to months. To avoid neuroimaging artifacts it is therefore recommended that patients undergo spinal imaging before lumbar puncture (DeAngelis, 1998; Mittl and Yousem, 1994). Similarly, for patients with primary CNS tumors, MR imaging of the spine should be performed before surgery or at a minimum of 14 to 21 days after surgery.

Cerebrospinal Fluid Flow Studies

Cerebrospinal fluid flow studies, using either ¹¹¹In-dium-diethylenetriamine pentaacetic acid (DTPA), ^{99m}Tc-Technetium-DTPA, or ^{99m}Tc-Technetium-human serum albumin, are an invaluable tool in the evaluation and treatment of leptomeningeal metastases (Chamberlain, 1995b). Cerebrospinal fluid flow studies provide a safe physiologic assessment of the clinical anatomy of spaces in the CSF (Chamberlain and Corey-Bloom, 1991; Grossman et al., 1982). The CSF circulates through the ventricular system and subarachnoid space that surrounds both the brain and spinal cord (Lyons and Meyer, 1990). Normally, the CSF is elaborated by the choroid plexus of the lateral and fourth ventricles and flows from lateral ventricles through the foramen of Monro and into the third ventricle and then through the aqueduct of Sylvius into the fourth ventricle. Exit of the CSF from the fourth ventricle is directed into the dorsal spinal subarachnoid space through the foramen of Magendie and into the basal cisterns through the lateral foramina of Luschka. Passage of the CSF through the foramen of Magendie into the valleculla and the beginning of downward flow into

the dorsal cervical subarachnoid space precedes the exit of CSF from the foramina of Luschka (Chiro et al., 1976). Cerebrospinal fluid then flows caudally through the dorsal spinal subarachnoid space, followed by its ascent into the ventral spinal subarachnoid space. Completion of the normal pattern of CSF circulation is by its ascent from the basal cisterns toward the superior sagittal sinus by way of migration over the cerebral convexities and along medial routes through the suprasellar and quadrigeminal cisterns.

Cerebrospinal fluid flow can be assessed following injection of the radionuclide via lumbar puncture or cisternal puncture or directly into the ventricles via an indwelling access device. Intraventricular and intralumbar routes of radionuclide administration reveal several of the same features of CSF flow. For instance, blockage to CSF flow that creates compartmentalization may affect the

1. Ventricular system
2. Basal cisterns or foramen magnum
3. Cervical subarachnoid space
4. Thoracic subarachnoid space
5. Lumbar subarachnoid space
6. Lateral cerebral convexity (sylvian cisterns)
7. High cerebral convexity (Chamberlain and Corey-Bloom, 1991; Grossman et al., 1982)

Radionuclide flow studies are superior for demonstrating interruption of the CSF flow versus contrast-enhanced CT, gadolinium-enhanced MRI, CT myelography, or contrast-enhanced MRI of the spine. This superiority in demonstrating CSF compartmentalization is independent of the route of radionuclide administration and may reflect the dynamic nature of the CSF flow, wherein radionuclide is passively car-

ried by the CSF bulk flow. Usual times of the appearance of radionuclides in the CSF compartments following intraventricular administration are given in Table 16-5.

Cerebrospinal fluid flow studies should be performed for solid tumor patients with leptomeningeal metastases before administration of intrathecal therapy. Of patients with leptomeningeal metastases, approximately one-third in studies by Chamberlain (1995b, 1998a) have abnormal flow better demonstrated by radionuclide flow studies versus CT myelography or MRI. Clinicians should realize that alterations in CSF flow are not limited to patients with bulky leptomeningeal metastases. In fact, radionuclide imaging studies have shown that as many as 70% of adult patients with leptomeningeal metastases have ventricular outlet obstruction, abnormal flow in the spinal canal, or impaired flow over the cerebral convexities (Grossman et al., 1982). It is important to identify patients with CSF flow abnormalities prospectively, as they can affect the distribution of intrathecal chemotherapy, leading to decreased efficacy or severe toxicity (Chamberlain, 1992; Chamberlain and Corey-Bloom, 1991).

Other studies suggest that CSF flow abnormalities appear to correlate with response to treatment and prognosis. It seems likely that impaired flow is an indirect measure of tumor burden and that more extensive flow abnormalities are associated with worse disease and prognosis (Chamberlain, 1998a; DeAngelis, 1998; Glantz et al., 1995; Mason et al., 1996). Obstruction to CSF flow is best addressed by the administration of involved-field radiotherapy at the site of the block. Approximately 50% of base of the brain and 25% to 30% of spinal subarachnoid blocks re-

Table 16-5. Time of Appearance (Minutes) for ¹¹¹Indium-DTPA Following Intraventricular and Lumbar Spinal Administration

	<i>Ventricular</i>	<i>Basal Cisterns</i>	<i>Foramen Magnum</i>	<i>Cervical Cord</i>	<i>Thoracic Cord</i>	<i>Lumbar Cord</i>	<i>Cerebral Convexity</i>
Intraventricular							
Median	0	1	7.5	15	20	30	50
Range	0-2	0-2	5-15	5-20	10-20	25-50	35-90
Lumbar							
Median	1440	30	25	15	1	0	1440
Range	na	20-40	15-35	10-25	1	0-2	na

na, no intermediate times measured.

Source: Adapted from Chamberlain (1992).

spond to limited-field radiotherapy or intrathecal chemotherapy with restoration of CSF flow (Chamberlain and Corey-Bloom, 1991).

In summary, the following recommendations regarding neuroradiographic evaluation can be made for a patient with suspected leptomeningeal metastases from a solid tumor. Contrast-enhanced CT or, preferably, gadolinium-enhanced MRI should be performed to define both dural-based and intraparenchymal bulk disease and to document the presence or absence of hydrocephalus. Computed tomography myelography or, particularly, contrast-enhanced MRI of the spine should be performed to define bulk disease, including intradural extramedullary tumor nodules and extradural lesions that compress the epidural spinal cord. For patients for whom treatment with intrathecal chemotherapy is a consideration, radionuclide CSF flow studies, either by intralumbar or intraventricular routes, should be performed to determine whether there is evidence of CSF compartmentalization.

TREATMENT

The varied manifestations of the heterogeneous group of malignancies that may result in leptomeningeal metastases preclude recommendations in favor of a single treatment approach. The primary treatment modalities for either presymptomatic or overt leptomeningeal metastases include radiotherapy, intrathecal chemotherapy, and high-dose systemic chemotherapy. Factors to consider when making specific treatment recommendations include the histopathology of the primary malignancy, the age of the patient, any history of prior CNS-directed therapy, the extent of systemic disease at initial diagnosis, and the presence or absence of abnormal CSF flow.

Presymptomatic or "preventative" CNS-directed therapy is a standard component of the front-line treatment for most patients who have leukemia or lymphoma. In addition, children who have CNS tumors with a predisposition for dissemination to the neuraxis (e.g., childhood medulloblastoma) may also receive presymptomatic treatment for leptomeningeal metastases (Heideman et al., 1997). It may be difficult to accurately assess the durability of response to treatment of patients with overt leptomeningeal metastases, especially those with underlying solid tumors, as therapy directed at leptomeningeal disease

is generally ineffective against the primary malignancy (Chamberlain et al., 1990; Glantz et al., 1995). Systemic cancer accounts for 50% to 60% of deaths of patients who have leptomeningeal metastases, and its treatment accounts for another 5% to 10% of deaths (Chamberlain, 1992; Grossman and Moynihan, 1991; Wasserstrom et al., 1982).

Response to treatment of leptomeningeal metastases is primarily evaluated by cytologic clearing of malignant cells from the CSF and secondarily by improvement of clinical signs or symptoms of leptomeningeal disease (Chamberlain, 1992; Grossman and Moynihan, 1991) and by lack of progression or improvement in neuroimaging studies. Given these considerations, treatment of leptomeningeal metastases from solid tumors is palliative and rarely curative, with a median patient survival of 4 to 6 months for those with overt disease (Chamberlain 1992, 1997; Grossman and Moynihan, 1991; Wasserstrom et al., 1982).

Radiotherapy

Treatment of leptomeningeal metastases with external beam radiotherapy is, with the exception of acute lymphocytic leukemia and some childhood brain tumors, directed at sites of symptomatic and bulky disease. This intervention is palliative, providing local control of and potential improvement in or resolution of neurologic deficits (DeAngelis, 1998; Grossman and Moynihan, 1991; Wasserstrom et al., 1982). External beam radiation to symptomatic sites, in either the cranium or spine, is often delivered to a total dose of 30 Gy in 10 fractions. This regimen is well tolerated, unlike whole neuraxis radiation, which results in significant morbidity with myelosuppression, and is not curative with the exceptions noted above. In addition to improvements in clinical signs and symptoms such as pain or weakness, directed radiotherapy may in some cases reduce or eliminate abnormalities in CSF flow. Restoration of CSF flow is a prerequisite for the safe administration of intrathecal chemotherapy.

Craniospinal irradiation alone or combined with intrathecal chemotherapy plus systemic chemotherapy may be curative for many children with hematologic malignancies. Craniospinal irradiation is also standard treatment for all patients with medulloblastoma. Craniospinal irradiation plus chemotherapy may be curative for some medulloblastoma patients

who have subarachnoid dissemination at initial diagnosis (Heideman et al., 1997).

The primary drawback of radiotherapy is that it can be associated with both acute and long-term sequelae; although these effects sometimes are difficult to differentiate from the effects of other aspects of therapy or from manifestations of the disease itself. Craniospinal irradiation may cause significant myelosuppression, as a substantial portion of active bone marrow is irradiated (Kun et al., 1984). Cranial irradiation may result in the "somnolence syndrome," which consists of a prodrome of anorexia and irritability followed by a variable period of somnolence from which recovery is spontaneous (Freeman et al., 1973). Although this syndrome is more often reported in the pediatric population, it may occur in adults (Faithfull and Brada, 1998; Goldberg et al., 1992). Long-term complications of cranial and craniospinal irradiation include neuroendocrine sequelae such as hypothyroidism (Voorhess et al., 1986; Pasqualini et al., 1991) and disturbances in the secretion of growth hormone (Blatt et al., 1984); neuropsychological sequelae such as decreases in intellect and mild to severe leukoencephalopathy (Moss, 1981; Paolucci and Rosito, 1983; Poplack and Brouwers, 1985); and secondary malignancies (Walter et al., 1998). Crossen et al. (1994) report that the long-term neurobehavioral sequelae occurring in adults following radiotherapy may be underestimated, in contrast with the pediatric population, because children are evaluated routinely for neuropsychological sequelae. Because of the potential for severe long-term complications from radiotherapy, the identification and application of effective and less-toxic treatment strategies for patients with neoplastic meningitis is a high priority.

Chemotherapy

Penetration of most systemically administered anti-neoplastic agents into the CSF is limited because malignant cells within the CNS are protected from the cytotoxic effects of systemic chemotherapy by the blood-brain and the blood-CSF barriers. To overcome the limitations imposed by the blood-CSF barrier, several pharmacological approaches for treatment and prophylaxis of meningeal malignancy with chemotherapy have been developed. These include (1) high-dose systemic administration of chemotherapy, (2) regional direct administration of cytotoxic

chemotherapeutic drugs into the CSF, and (3) pharmacokinetically guided dosing to achieve a target CSF drug exposure. Each approach has distinct advantages and disadvantages.

High-Dose Systemic Chemotherapy

The limited CSF penetration of some chemotherapeutic agents can be overcome by administering high doses of the drug systemically. Advantages of this approach include a more uniform distribution of the drug through the neuraxis and better penetration of cytotoxic concentrations of drug into the brain parenchyma and perivascular (Virchow-Robin) spaces. Protracted infusions may result in an equilibrium being reached between plasma and CSF drug levels, resulting in cytotoxic CSF drug concentrations for a prolonged period. In a retrospective study of high-dose methotrexate, Glantz and colleagues (1998) found that this strategy has limited application for the treatment of neoplastic meningitis from solid tumors. Conversely, it has been effectively employed using methotrexate and cytarabine in the treatment and prevention of CNS leukemias and lymphomas (Balis et al., 1985).

Although methotrexate penetration into the CSF is limited (CSF/plasma ratio of 0.03 [Bleyer et al., 1978]), the use of leucovorin calcium rescue along with the administration of very high doses can circumvent this poor penetration. With this approach, cytotoxic concentrations of methotrexate can be achieved within the CSF with doses as high as 33,600 mg/m² and tolerance of an infusion duration as long as 42 hours before administration of leucovorin (Balis et al., 1985). Whereas regimens using very high-dose systemic methotrexate have been effective, the optimal dose and schedule necessary for efficacious systemic therapy of CNS leukemia has not been clarified. A rational approach to dosing of this and other agents for the treatment of leptomeningeal metastases is to attain a CSF drug concentration and/or duration greater than the optimal in vitro concentration and/or duration. Because rescue agents are not available for many anticancer agents, this strategy is generally not feasible. However, the relative ease of autologous peripheral blood stem cell rescue technology has led to a resurgence of clinical trials that incorporate higher than standard doses of chemotherapy. The impact of this approach on efficacy and long-term sequelae is not yet known.

Cytarabine penetrates into the CSF more effectively than methotrexate and has a CSF/plasma ratio of 0.18 to 0.33 (Donehower et al., 1986). Following systemic infusion of cytarabine, the CSF drug concentration will eventually exceed that in plasma because cytarabine is not deaminated within the CSF but is rapidly deaminated in plasma (Lopez et al., 1985). High-dose regimens of 2 to 3 g/m² administered every 12 hours will result in persistent cytotoxic concentrations of cytarabine in the CSF. Although high-dose intravenous cytarabine has been shown to be efficacious in the treatment of meningeal leukemia (Frick et al., 1984), this approach is associated with significant systemic toxicity and may also be associated with neurotoxicity. Neurotoxicity, primarily in the form of severe and potentially irreversible cerebellar dysfunction, appears to occur in a dose-dependent manner, with an increased incidence in patients who receive total doses exceeding 24 g/m² (Herzig et al., 1985; Barnett et al., 1985).

Another approach to systemic therapy utilizes pharmacokinetic monitoring to adjust drug doses in individual patients in an attempt to achieve a target exposure duration threshold that has previously been defined in preclinical studies (Zamboni et al., 1998). An example of this approach is the studies performed by Zamboni et al. (1998) with topotecan, a topoisomerase I inhibitor with preclinical activity against medulloblastoma cell lines and xenografts (Houghton et al., 1995). In vitro studies in medulloblastoma cell lines were performed to define the optimal duration and extent of drug exposure required in vivo. Pharmacokinetic studies were then performed in nonhuman primates to determine the optimal dose and administration schedule required to achieve the desired exposure throughout the subarachnoid space.

On the basis of these results, a phase II clinical trial with children with high-risk medulloblastoma was initiated. Topotecan was administered as a 4 hour infusion for 5 consecutive days; the dosage was pharmacokinetically adjusted to attain the target concentration defined in preclinical studies. In addition, serial CSF samples were obtained to determine the length of time that drug exposure in the CSF exceeded the target concentration (Zamboni et al., 1998). The primary advantage of this approach is that it helps to ensure that an individual patient achieves the target drug exposure in both plasma and CSF, which may be very important for agents with marked interindividual differences in pharmacokinetic disposition.

The primary disadvantage of this approach is that it requires numerous resources and may not be feasible in a multi-institutional, cooperative group setting, particularly for drugs that are chemically unstable. Further studies are required to determine the impact of this approach on therapeutic outcome.

Regional Cerebrospinal Fluid Therapy

Regional (intrathecal) administration of chemotherapy was one of the first approaches taken for the treatment of leptomeningeal metastases after the limitations of systemic chemotherapy were recognized. Direct administration of drugs into the CSF results in concentrations at the target site (the meninges) using relatively small doses because of the small volume of distribution (140 ml in CSF versus 3500 ml in plasma) and the relatively slow clearance of many drugs after intrathecal dosing (Poplack et al., 1980). As a result, cytotoxic concentrations may be attained in the CSF at a fraction of the dose that would have to be administered systemically to achieve the same concentration (Collins, 1987). Thus, systemic toxicity is rare when chemotherapy is delivered intrathecally.

In the treatment and prevention of leptomeningeal metastases secondary to leukemia or lymphoma, intrathecal drugs are most commonly administered via lumbar puncture. However, ventricular access devices, such as Ommaya reservoirs, are routinely employed for the treatment of leptomeningeal metastases secondary to an underlying primary CNS or solid tumor because of the limitations of intralumbar chemotherapy. In addition to the pain and inconvenience associated with lumbar punctures, radioisotope studies have demonstrated that in approximately 10% of intrathecal injections drug is not delivered into the subarachnoid space but rather into the subdural or epidural space (Larson et al., 1981). There may also be limited and variable drug distribution into the ventricular CSF after an intralumbar injection secondary to the unidirectional flow of the CSF or because of rapid elimination or metabolism of drug in the intrathecal space (Shapiro et al., 1975). Distribution may be further compromised because of alterations in CSF flow associated with disease (Poplack et al., 1980) or patient positioning (Blaney et al., 1995b).

Direct intraventricular administration of chemotherapy overcomes some of the limitations associated with intralumbar injections. Ventricular reservoirs circumvent the problems of local CSF leakage or

epidural or subdural administration. Distribution of drug within the CSF is more complete because the drug no longer has to diffuse in an opposite direction from CSF bulk flow (Blasberg et al., 1977; Shapiro et al., 1975, 1977). Administration through a ventricular reservoir is also associated with less discomfort for patients and allows flexibility in dosing schedules such as the "concentration times time" ($C \times T$) approach. Repeated intraventricular administration of low-dose chemotherapy over a relatively short period increases the duration of CSF exposure to cytotoxic drug concentrations, an important determinant of cytotoxicity for cell cycle-specific agents such as methotrexate and cytarabine (Bleyer et al., 1978). In addition, the $C \times T$ approach may potentially reduce neurotoxicity by avoiding excessively high peak drug concentrations and reducing the total dose of administered drug (Bleyer et al., 1978). The obvious drawback of this method is that, because it requires surgical placement of an indwelling subcutaneous reservoir, there may be an increased risk of infection. In addition, no clinical studies have demonstrated a survival advantage for patients with leptomeningeal metastases who receive drugs into the CSF through the ventricular route compared with the lumbar route (Hitchins et al., 1987). Unfortunately, even regional delivery of cytotoxic drugs directly into the CSF via the intralumbar or intraventricular route has limitations because intrathecally administered drugs penetrate only very short distances into brain parenchyma and tumors. Drug penetration into nodules 2 to 3 mm in diameter is possible, but penetration of effective drug doses into 5 mm nodules is not feasible (Blasberg et al., 1977).

Intrathecal methotrexate therapy, developed nearly 30 years ago for the treatment of overt meningeal leukemia, remains the most commonly used intrathecal agent. The pharmacokinetic principle of age-based dosing rather than dosing based on body surface area for intrathecal agents was derived from early clinical studies involving intrathecal methotrexate. These studies demonstrated that CSF volume is an important factor in CSF drug distribution after intrathecal administration. In children, CSF volume increases much more rapidly than body surface area so that by the time a child is 3 years of age this volume is essentially equivalent to that of an adult (Fig. 16-1). Using age, rather than body surface area, to determine appropriate dosing of intrathecal methotrexate resulted in a reduced neurotoxicity and lower inci-

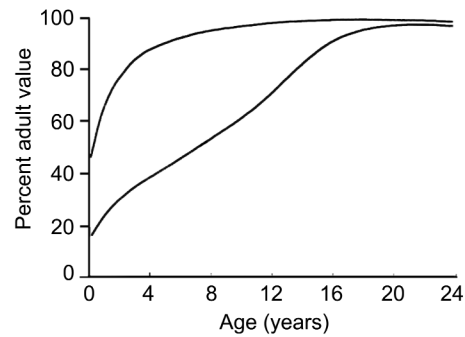


Figure 16-1. Relationship between CNS volume (upper curve) and body surface area (lower curve) as a function of age. CNS volume increases at a more rapid rate than body surface area, reaching the adult volume by 3 years of age. (Reproduced with permission from Bleyer, 1977.)

dence of CNS relapse (Bleyer, 1977, 1983). Thus, because CSF volume increases much more rapidly than body surface area, dosages for all agents administered by the intrathecal route should be based on patient age (unlike systemic administration of chemotherapy).

Other drugs routinely administered by the intrathecal route include cytarabine, hydrocortisone, and thiotepa. DTC101, a sustained-release formulation of cytarabine, has recently been approved by the Food and Drug Administration for the treatment of lymphomatous meningitis in adults (Glantz et al., 1999). It should be noted that the disposition and metabolism of drugs may vary after intrathecal versus systemic administration. For example, cytarabine is rapidly converted to the inactive metabolite uracil arabinoside (ara-U) by a ubiquitous enzyme, cytidine deaminase, after intravenous administration (Camiener and Smith, 1965). In contrast, after intrathecal injection, conversion to ara-U is negligible because of the significantly lower cytidine deaminase activity in the brain and CSF. This difference is partially responsible for the more prolonged half-life of cytarabine in the CSF versus in plasma. This and the fact that cytarabine clearance from the CSF is only slightly more rapid than bulk flow absorption from the CSF (Fulton et al., 1982; Zimm et al., 1984) favors the intrathecal route of cytarabine administration for leptomeningeal disease. Likewise, after systemic administration thiotepa is converted to the active metabolite TEPA. Both thiotepa and TEPA readily cross the blood-brain barrier, providing essentially identical

drug exposure in the plasma and CSF. However, after intrathecal thiotepa administration drug is rapidly cleared from the CSF (nine times the rate of CSF bulk flow), which limits drug distribution throughout the neuraxis. In addition, TEPA is not detectable in the CSF following intrathecal administration (Strong et al., 1986).

The impact of regional therapy on the outcome of patients with leptomeningeal metastases is difficult to address because only a limited number of clinical trials have been performed with this patient population. Clinical trials for the treatment of leptomeningeal metastases are complicated by many factors, including the heterogeneous spectrum and inherent chemosensitivity of the underlying primary tumor; the advanced stage of many patients at presentation; and difficulties inherent in defining cytologic and radiographic response, especially in patients receiving concomitant systemic chemotherapy for the treatment of systemic or bulk CNS disease.

Intrathecal chemotherapy is associated with distinct toxic effects that may be acute, subacute, or delayed. Chemical arachnoiditis, an acute toxic effect common to both methotrexate and cytarabine, is characterized by headache, nuchal rigidity, vomiting, fever, and CSF pleocytosis occurring within hours to 1 to 2 days after administration of the drug (Pizzo et al., 1979). Less frequently, intrathecal cytarabine can result in acute neurotoxic effects consisting of seizures or paraplegia (Eden et al., 1978; Wolff et al., 1979). Within days or weeks after administration of intrathecal methotrexate, a subacute myelopathy or encephalopathy may occur that is sometimes irreversible (Pizzo et al., 1979; Bleyer, 1981). This syndrome is characterized by a weakness of limbs, cranial nerve palsies, ataxia, visual impairment, seizures, and coma. Leukoencephalopathy, a chronic, progressive demyelinating encephalopathy, is a delayed toxicity that can appear months to years after treatment with intrathecal methotrexate and cranial irradiation. The encephalopathy consists of dementia, spastic paralysis, seizures, and coma. Whereas arachnoiditis is noted to occur in adults, other acute, subacute, and delayed toxicities have been reported, primarily in the pediatric population.

Accidental intrathecal drug overdose, usually the result of inadvertent intrathecal injection of a higher dose appropriate for systemic administration, can produce severe and frequently lethal toxic effects. Extreme caution must therefore be exercised by clini-

cians administering drugs by this route. With the widespread use of intrathecal chemotherapy, however, the possibility of fatal dosing errors will continue to exist. In an effort to rescue patients who accidentally receive high doses of methotrexate intrathecally (the most frequent type of overdose), intrathecal administration of carboxypeptidase G2 (CPDG₂), a recombinant bacterial enzyme capable of rapidly inactivating methotrexate by cleaving its glutamate residue, has been studied in a nonhuman primate model (Adamson et al., 1991b). Administration of CPDG₂ following otherwise lethal doses of intrathecal methotrexate saved animals from death by decreasing the methotrexate concentration in CSF by more than 100-fold within 5 minutes of enzyme administration. The successful use of CPDG₂ in conjunction with ventriculolumbar perfusion for the treatment of inadvertent intrathecal methotrexate overdose in humans has also been reported (O'Maricaigh et al., 1996).

NEW PHARMACOLOGIC APPROACHES

The need to develop new approaches and combination therapy for the treatment of leptomeningeal metastases is an area of ongoing research. Evaluating the safety and effectiveness of chemotherapeutic agents administered intrathecally presents unique challenges not encountered in evaluating systemically administered drugs. For phase I (toxicity and dose-schedule trial) development of a new intrathecal agent, the classic approach, in which cohorts of patients receive progressively escalated doses until toxic effects are consistently observed, is not appropriate because the expected dose-limiting toxicity is neurologic. The wide experience with intrathecal methotrexate provides ample evidence for exercising extreme caution when escalating intrathecal doses of a drug. In studies of patients treated with doses of intrathecal methotrexate based on body surface area, neurotoxicity was found to correlate with an elevated concentration of the drug in the CSF (Bleyer et al., 1977). The manifestations of neurotoxic effects were often irreversible or fatal and included severe meningismus, sustained grand mal seizures, irreversible cerebellar dysfunction, quadriplegia, and fatal myelopathy.

Characteristics of an optimal intrathecal agent include:

1. Demonstration of cytotoxicity in in vitro and in vivo models
2. Absence of neurotoxicity following systemic administration
3. Novel mechanism of antitumor activity
4. Formulation suitable for intrathecal administration

Our laboratory has taken a three-step approach to the development of new intrathecal chemotherapeutic agents using a nonhuman primate model and in vitro cytotoxicity studies. Initially, a target cytotoxic concentration and schedule dependency of a drug is determined in vitro using human tumor cell lines. Next, the CSF and plasma pharmacokinetics of the drug following intrathecal dosing are determined in the nonhuman primate. When the intrathecal dose of a drug has been calculated to achieve or exceed the desired cytotoxic effect in the CSF and has been proven safe to administer in the nonhuman primate, a phase I trial in humans is initiated, with escalation of the dose to the target cytotoxic concentration of drug exposure. The pharmacokinetic parameters derived in the nonhuman primate predict human CSF pharmacokinetics, after known differences in CSF volume and bulk flow rate are corrected for, and are the basis for the starting dose in the phase I trial. Typically, the starting dose for phase I clinical trials is approximately 10% to 20% of the dose shown to exceed cytotoxic concentrations in nonhuman primates. Several agents that have been developed using this approach are summarized below.

Mafosfamide

Mafosfamide, a chemically stable thioethane sulfonic acid salt of cyclophosphamide, is a preactivated derivative of cyclophosphamide that, unlike cyclophosphamide, does not require activation by hepatic microsomal enzymes to express an antitumor effect. Mafosfamide has a spectrum of antitumor activity similar to cyclophosphamide, and an in vitro cytotoxic target concentration has been defined. Preclinical pharmacokinetic studies in a nonhuman primate model showed that, after intrathecal dosing, ventricular CSF mafosfamide concentrations in excess of in vitro cytotoxic levels could be attained at doses that were not associated with systemic or neurologic toxicity.

On the basis of these results, a phase I study currently nearing completion was initiated with patients

with leptomeningeal metastases (Blaney et al., 1992). In addition, the feasibility of administering intrathecal mafosfamide in infants and young children with newly diagnosed primary CNS embryonal tumors, tumors with a known predilection for leptomeningeal spread, is currently being evaluated in a Pediatric Brain Tumor Consortium study (SM Blaney is the PI).

Topotecan

Topotecan, a topoisomerase I inhibitor that has demonstrated promising evidence of antitumor activity against a broad spectrum of tumors, is another example of an agent with a novel mechanism of action that has entered clinical trials after initial evaluation in the nonhuman primate model. Preclinical studies in nonhuman primates revealed that intraventricular topotecan administration was safe and was not associated with either systemic or neurologic toxicity.

Following administration of a 0.1 mg intraventricular dose, the ventricular CSF drug exposure to the parent drug was 450-fold greater than following intravenous administration of a 40-fold higher dose (10 mg/m²). In addition, peak lumbar levels approached 1 μ M. Plasma levels of both the lactone and opening form were not measurable. Thus, compared with systemic topotecan administration, intrathecal administration resulted in a dramatic pharmacokinetic advantage of drug exposure in the CNS. Furthermore, there were no significant systemic or neurologic toxicities associated with intrathecal topotecan administration in nonhuman primates (Blaney et al., 1993, 1995a). A phase I study of intrathecal topotecan has recently been completed (Blaney et al., 1998), and a phase II study for children with leptomeningeal metastases has been initiated in the Children's Oncology Group.

Other Cytotoxic Agents

The same approach has been used in the development of several other intrathecal agents, including 6-mercaptopurine (Adamson et al., 1991a), diaziquone (Berg et al., 1992a), and sustained-release cytarabine (DTC101) (Kim et al., 1993). In addition, other agents were not brought to clinical trial after unexpected neurologic toxic effects were observed in the nonhuman primate. 5-Fluorouracil administered into the lumbar space resulted in significant injury to the

spinal cord in a cohort of animals, and that drug was deemed unsafe for clinical trial (Berg et al., 1992b). Neuropathologic studies demonstrated local necrosis of the spinal cord at the level of intrathecal drug administration. Similarly, a series of other anticancer agents administered intrathecally to experimental animals resulted in paralysis or death (Table 16–6). Using a preclinical model has thus averted the testing of drugs that could result in severe or irreversible neurotoxic effects when administered intrathecally to patients.

Monoclonal Antibodies

Monoclonal antibodies have the theoretical advantage of selectively targeting malignant cells expressing specific antigens while sparing normal tissues that do not express the same epitopes (Berg and Poplack, 1995). Several preliminary studies have been performed in which tumor-specific monoclonal antibodies were conjugated to ¹³¹Iodine isotope in doses from 25 to 160 mCi and administered intrathecally (Brown et al., 1996; Coakham and Kemshead, 1998; Pizer and Kemshead, 1994; Kemshead et al., 1998). Acute toxicities following intrathecal monoclonal antibody administration include aseptic meningitis and myelosuppression. A long-term follow-up report of 52 patients treated with ¹³¹Iodine-labeled antibodies between 1984 and 1993 showed the best results in patients with primitive neuroectodermal tumors (n = 22) with 53% of evaluative cases having responses and 11% demonstrating stable disease. The mean survival of responders was 39 months compared with 4

months for nonresponders (Coakham and Kemshead, 1998). Additional studies are needed to better define the role of this therapy for leptomeningeal metastases.

Immunotoxins

Preclinical studies with animal models have evaluated the treatment of leptomeningeal metastases with intrathecal administration of monoclonal antibodies conjugated to myriad immunotoxins, including M6-ricin A-chain immunotoxin, B43 (anti CD19) pokeweed antiviral protein, and anti-CD7-ricin A-chain immunotoxin (Zovickian and Youle, 1988; Gunther et al., 1995; Herrlinger et al., 1998). Antitumor effects have been observed in these preclinical studies. Laske et al. (1997) reported the findings of a phase I study using intraventricular 454A12-rRA in patients with leptomeningeal spread of systemic neoplasm. In patients receiving 120 μ g, toxicity with CSF inflammation resulting in transient headache, vomiting, and altered mental status was seen. The acute inflammation was responsive to steroids and CSF drainage. No systemic toxicity was identified. Four of the eight patients studied had a transient reduction in CSF tumor cell counts. Further clinical trials are needed to evaluate the utility of this therapeutic approach for patients with leptomeningeal metastases.

Gene Therapy

The feasibility of administering adenoviral gene vectors in rat models of leptomeningeal disease has been demonstrated (Ram et al., 1994; Rosenfeld et

Table 16–6. Antineoplastic Agents that Produced Unexpected Neurotoxicity When Administered to the Rhesus Monkey for Pharmacokinetic Evaluation

<i>Drug</i>	<i>Dose</i>	<i>Animals</i>	<i>Neurotoxicity (N)</i>
Melphalan (Berg et al., 1994)	1	3	Hind-limb paralysis (2/3); death (1/3)
5-Fluorouracil (Berg et al., 1992a)	10	2	Hind-limb paralysis (3/3)
	1	1	
6-Thioguanine (Poplack, 1992, personal communication)	1.5	1	Hind-limb dysfunction (2/2)
	0.5	1	
Cisplatin (Gormley et al., 1981)	0.5*	1	Death
CPE-C (Poplack, 1992, personal communication)	2	3	Hind-limb dysfunction (2/3)
Trimetrexate (Poplack, 1992, personal communication)	5*	2	Agitation and respiratory depression (1/2); irreversible respiratory depression (1/2)

Unless otherwise indicated, all drugs were administered into the lumbar space.

*Drug was only administered via a ventricular reservoir.

al., 1997). Recent studies have also described the distribution of adenoviral gene vectors and the pharmacokinetics of the antiviral drug ganciclovir in the nonhuman primate model (Driesse et al., 1999; Serabe et al., 1999). Preclinical studies to assess the feasibility and distribution after intralumbar injection of an adenoviral vector to nonhuman primates are in progress. This novel therapeutic approach may have potential application for the treatment of patients with leptomeningeal metastases; however, extensive preclinical and clinical studies are still required.

CONCLUSION

The successful treatment of leptomeningeal metastases continues to pose a significant challenge to the clinical oncologist. Research efforts to date have focused on the identification, dosage, and safety of new intrathecal and intraventricular chemotherapeutic agents or other treatment modalities as well as on methods to improve upon the use of currently available agents. While considerable progress has been made during the past several decades in the treatment and prevention of leptomeningeal leukemias and lymphomas, such progress has not been realized for patients with leptomeningeal metastases arising from and underlying solid or primary CNS tumors. Research using combination chemotherapy and other novel therapies, including monoclonal antibodies, immunotoxins, and gene therapy, must be pursued. Well-designed clinical trials that focus on efficacy, disease-free progression, and quality of life will be critical for evaluating the impact of these developments in patients with leptomeningeal metastases.

REFERENCES

- Adamson PC, Balis FM, Arndt CA, et al. 1991a. Intrathecal 6-mercaptopurine: preclinical pharmacology, phase I/II trial, and pharmacokinetic study. *Cancer Res* 51:6079-6083.
- Adamson PC, Balis FM, McCully CL, et al. 1991b. Rescue of experimental intrathecal methotrexate overdose with carboxypeptidase-G2. *J Clin Oncol* 9:670-674.
- Balis FM, Savitch JL, Bleyer WA, Reaman GH, Popleck DG. 1985. Remission induction of meningeal leukemia with high-dose intravenous methotrexate. *J Clin Oncol* 3:485-489.
- Barnett MJ, Richards MA, Ganesan TS, et al. 1985. Central nervous system toxicity of high-dose cytosine arabinoside. *Semin Oncol* 12(suppl 3):227-232.
- Berg SL, Balis FM, McCully CL, Parker GA, Murphy RF, Popleck DG. 1992a. Intrathecal 5-fluorouracil in the rhesus monkey. *Cancer Chemother Pharmacol* 31:127-130.
- Berg SL, Balis FM, Zimm S, et al. 1992b. Phase I/II trial and pharmacokinetics of intrathecal diaziquone in refractory meningeal malignancies. *J Clin Oncol* 10:143-148.
- Berg S, Balis FM, McCully CL, Popleck DG. 1994. Re: toxicity of intrathecal melphalan. *J Natl Cancer Inst* 86:463.
- Berg SL, Popleck DG. 1995. Advances in the treatment of meningeal cancers. *Crit Rev Oncol Hematol* 20:87-98.
- Blaney SM, Balis F, Murphy R, et al. 1992. A phase I study of intrathecal mafosfamide (mf) in patients with refractory meningeal malignancies. *Proc ASCO* 11:113.
- Blaney SM, Cole DE, Balis FM, Godwin K, Popleck DG. 1993. Plasma and cerebrospinal fluid pharmacokinetic study of topotecan in nonhuman primates. *Cancer Res* 53:725-727.
- Blaney SM, Cole DE, Godwin K, McCully CL, Murphy R, Balis FM. 1995a. Intrathecal administration of topotecan in nonhuman primates. *Cancer Chemother Pharmacol* 36:121-124.
- Blaney S, Heideman R, Cole D, et al. 1998. A phase I study of intrathecal topotecan. *Proc Am Assoc Cancer Res* 39:322.
- Blaney SM, Popleck DG, Godwin K, McCully CL, Murphy R, Balis FM. 1995b. Effect of body position on ventricular CSF methotrexate concentration following intralumbar administration. *J Clin Oncol* 13:177-179.
- Blasberg RG, Patlak CS, Shapiro WR. 1977. Distribution of methotrexate in the cerebrospinal fluid and brain after intraventricular administration. *Cancer Treat Rep* 61:633-641.
- Blatt J, Bercu BB, Gillin JC, Mendelson WB, Popleck DG. 1984. Reduced pulsatile growth hormone secretion in children after therapy for acute lymphoblastic leukemia. *J Pediatr* 104:182-186.
- Bleyer WA. 1977. Clinical pharmacology of intrathecal methotrexate. II. An improved dosage regimen derived from age related pharmacokinetics. *Cancer Treat Rep* 61:1419-1425.
- Bleyer WA. 1981. Neurologic sequelae of methotrexate and ionizing radiation: a new classification. *Cancer Treat Rep* 65:89-98.
- Bleyer W. 1983. Central nervous system leukemia. In: Gunz FW, Henderson ES (eds), William Dameshek and Frederick Gunz's Leukemia, 4th ed. New York: Grune & Stratton, 865 pp.
- Bleyer WA, Coccia PF, Sather HN, et al. 1983. Reduction in central nervous system leukemia with a pharmacokinetically derived intrathecal methotrexate dosage regimen. *J Clin Oncol* 1:317-325.
- Bleyer W, Popleck D, Simon R. 1978. "Concentration \times time" methotrexate via a subcutaneous reservoir: a less toxic regimen for intraventricular chemotherapy of central nervous system neoplasms. *Blood* 51:835-842.
- Brown MT, Coleman RE, Friedman AH, et al. 1996. Intrathecal ¹³¹I-labeled antitenascin monoclonal antibody 81C6 treatment of patients with leptomeningeal neoplasms or primary brain tumor resection cavities with subarachnoid communication: phase I trial results. *Clin Cancer Res* 2:963-972.
- Camiener GW, Smith CG. 1965. Studies of the enzymatic deam-

- ination of cytosine arabinoside. I. Enzyme distribution and species specificity. *Biochem Pharmacol* 14:1405-1416.
- Chamberlain MC. 1992. Current concepts in leptomeningeal metastasis. *Curr Opin Oncol* 4:533-539.
- Chamberlain MC. 1995a. A review of leptomeningeal metastases in pediatrics. *J Child Neurol* 10:191-199.
- Chamberlain MC. 1995b. Comparative spine imaging in leptomeningeal metastases. *J Neurooncol* 23:233-238.
- Chamberlain MC. 1997. Pediatric leptomeningeal metastases: outcome following combined therapy. *J Child Neurol* 12:53-59.
- Chamberlain MC. 1998a. Radioisotope CSF flow studies in leptomeningeal metastases. *J Neurooncol* 38:135-140.
- Chamberlain MC. 1998b. Cytologically negative carcinomatous meningitis: usefulness of CSF biochemical markers. *Neurology* 50:1173-1175.
- Chamberlain MC, Corey-Bloom J. 1991. Leptomeningeal metastases: ¹¹¹indium-DTPA CSF flow studies. *Neurology* 41:1765-1769.
- Chamberlain MC, Durr L. 1993. Involved field radiotherapy and intra-Ommaya methotrexate/cytarabine in patients with AIDS-related lymphomatous meningitis. *J Clin Oncol* 11:1978-1984.
- Chamberlain MC, Kormanik PA. 1997. Non-AIDS related lymphomatous meningitis: combined modality therapy. *Neurology* 49:1728-1731.
- Chamberlain MC, Sandy AD, Press GA. 1990. Leptomeningeal metastasis: a comparison of gadolinium-enhanced MR and contrast-enhanced CT of the brain. *Neurology* 40:435-438.
- Chiro GD, Hammock MK, Bleyer WA. 1976. Spinal descent of cerebrospinal fluid in man. *Neurology* 26:1-8.
- Cibas ES, Malkin MG, Posner JB, Melamed MR. 1987. Detection of DNA abnormalities by flow cytometry in cells from cerebrospinal fluid. *Am J Clin Pathol* 88:570-577.
- Coakham HB, Brownell B, Harper EI, et al. 1984. Use of monoclonal antibody panel to identify malignant cells in the cerebrospinal fluid. *Lancet* 1:1095-1098.
- Coakham HB, Kemshead JT. 1998. Treatment of neoplastic meningitis by targeted radiation using (¹³¹I)-radiolabelled monoclonal antibodies. Results of responses and long term follow-up in 40 patients. *J Neurooncol* 38:225-232.
- Collins J. 1987. Regional therapy: an overview. In: Poplack DG, Massimo L, Cornaglia-Ferraris P (eds), *The Role of Pharmacology in Pediatric Oncology*. Boston: Martinus Nijhoff Publishers, pp125-135.
- Crossen JR, Garwood D, Glatstein E, Neuwelt EA. 1994. Neurobehavioral sequelae of cranial irradiation in adults: a review of radiation-induced encephalopathy. *J Clin Oncol* 12:627-642.
- DeAngelis LM. 1998. Current diagnosis and treatment of leptomeningeal metastasis. *J Neurooncol* 38:245-252.
- Donehower R, Karp JE, Burke PJ. 1986. Pharmacology and toxicity of high dose cytarabine by 72-hour continuous infusion. *Cancer Treat Rep* 70:1059-1065.
- Driesse MJ, Kros JM, Avezaat CJ, et al. 1999. Distribution of recombinant adenovirus in the cerebrospinal fluid of non-human primates. *Hum Gene Ther* 10:2347-2354.
- Eden OB, Goldie W, Wood T, Etcubanas E. 1978. Seizures following intrathecal cytosine arabinoside in young children with acute lymphoblastic leukemia. *Cancer* 42:53-58.
- Ernerudh J, Olsson T, Berlin G, von Schenck H. 1987. Cerebrospinal fluid immunoglobulins and β_2 -microglobulin in lymphoproliferative and other neoplastic diseases of the central nervous system. *Arch Neurol* 44:915-920.
- Faithfull S, Brada M. 1998. Somnolence syndrome in adults following cranial irradiation for primary brain tumors. *Clin Oncol* 10:250-254.
- Fouladi M, Gajjar A, Boyett JM, et al. 1999. Comparison of CSF cytology and spinal magnetic resonance imaging in the detection of leptomeningeal disease in pediatric medulloblastoma or primitive neuroectodermal tumor. *J Clin Oncol* 17:3234-3237.
- Freeman J, Johnston PG, Voke JM. 1973. Somnolence after prophylactic cranial irradiation in children with acute lymphoblastic leukaemia. *BMJ* 4:523-525.
- Freilich RJ, Krol G, DeAngelis LM. 1995. Neuroimaging and cerebrospinal fluid cytology in the diagnosis of leptomeningeal metastasis. *Ann Neurol* 38:51-57.
- Frick J, Ritch PS, Hansen RM, Anderson T. 1984. Successful treatment of meningeal leukemia using systemic high-dose cytosine arabinoside. *J Clin Oncol* 2:365-368.
- Fulton DS, Levin VA, Gutin PH, et al. 1982. Intrathecal cytosine arabinoside for the treatment of meningeal metastases from malignant brain tumors and systemic tumors. *Cancer Chemother Pharmacol* 8:285-291.
- Glanz MJ, Cole BF, Recht L, et al. 1998. High-dose intravenous methotrexate for patients with nonleukemic leptomeningeal cancer: is intrathecal chemotherapy necessary? *J Clin Oncol* 16:1561-1567.
- Glanz MJ, Hall WA, Cole BF, et al. 1995. Diagnosis, management, and survival of patients with leptomeningeal cancer based on cerebrospinal fluid-flow status. *Cancer* 75:2919-2931.
- Glanz MJ, LaFollette S, Jaeckle KA, et al. 1999. Randomized trial of a slow-release versus a standard formulation of cytarabine for the intrathecal treatment of lymphomatous meningitis. *J Clin Oncol* 17:3110-3116.
- Goldberg SL, Tefferi A, Rummans TA, Chen MG, Solberg LA, Noel P. 1992. Post-irradiation somnolence syndrome in an adult patient following allogeneic bone marrow transplantation. *Bone Marrow Transplant* 9:499-501.
- Gormley PE, Gangji D, Wood JH, Poplack DG. 1981. Pharmacokinetic study of cerebrospinal fluid penetration of cis-diamminedichloroplatinum (II). *Cancer Chemother Pharmacol* 5:257-260.
- Grossman SA, Moynihan TJ. 1991. Neoplastic meningitis. *Neurol Clin* 9:843-856.
- Grossman SA, Trump CL, Chen DC, Thompson G, Murray K, Wharam M. 1982. Cerebrospinal fluid flow abnormalities in patients with neoplastic meningitis. An evaluation using ¹¹¹indium-DTPA ventriculography. *Am J Med* 73:641-647.
- Gunther R, Chelstrom LM, Tuel-Ahlgren L, Simon J, Myers DE, Uckan FM. 1995. Biotherapy for xenografted human central nervous system leukemia in mice with severe combined immunodeficiency using B43 (anti-CD19)-pokeweed antiviral protein immunotoxin. *Blood* 85:2537-2545.
- Harrison SK, Ditchfield MR, Waters K. 1998. Correlation of MRI and CSF cytology in the diagnosis of medulloblastoma spinal metastases. *Pediatr Radiol* 28:571-574.
- Heideman RL, Packer RJ, Albright A, et al. 1997. Tumors of the central nervous system. In: Pizzo Pa, Poplack DG (eds), *Principles and Practice of Pediatric Oncology*, 3rd ed. Philadelphia: Lippincott-Raven, pp 633-697.

- Herrlinger U, Schmidberger H, Buchholz R, Wehrmann M, Valleria DA, Schabet M. 1998. Intrathecal therapy of leptomeningeal CEM T-cell lymphoma in nude rats with anti-CD7 ricin toxin A chain immunotoxin. *J Neurooncol* 40:1-9.
- Herzig RH, Lazarus HM, Herzig GP, Coccia PF, Wolff SN. 1985. Central nervous system toxicity with high-dose cytosine arabinoside. *Semin Oncol* 12(suppl 3):233-236.
- Hitchins RN, Bell DR, Woods RL, Levi JA. 1987. A prospective randomized trial of single-agent versus combination chemotherapy in meningeal carcinomatosis. *J Clin Oncol* 5:1655-1662.
- Houghton PJ, Cheshire PJ, Hallman JD 2nd, et al. 1995. Efficacy of topoisomerase I inhibitors, topotecan and irinotecan, administered at low dose levels in protracted schedules to mice bearing xenografts of human tumors. *Cancer Chemother Pharmacol* 36:393-403.
- Kallmes DF, Gray L, Glass JP. 1998. High-dose gadolinium-enhanced MRI for diagnosis of meningeal metastases. *Neuroradiology* 40:23-26.
- Kaplan JG, DeSouza TG, Farkash A, et al. 1990. Leptomeningeal metastases: comparison of clinical features and laboratory data of solid tumors, lymphomas and leukemias. *J Neurooncol* 9:225-229.
- Kemshead JT, Hopkins K, Pizer B., et al. 1998. Dose escalation with repeated intrathecal injections of 131I-labelled MAbs for the treatment of central nervous system malignancies. *Br J Cancer* 77:2324-2330.
- Kim KS, Ho SU, Weinberg PE, Lee C. 1982. Spinal leptomeningeal infiltration by systemic cancer: myelographic features. *Am J Roentgenol* 139:361-365.
- Kim S, Khatibi S, Howell SB, McCully C, Balis FM, Poplack DG. 1993. Prolongation of drug exposure in cerebrospinal fluid by encapsulation into DepoFoam. *Cancer Res* 53:1596-1598.
- Klee GG, Tallman RD, Goellner JR, Yanagihara T. 1986. Elevation of carcinoembryonic antigen in cerebrospinal fluid among patients with meningeal carcinomatosis. *Mayo Clin Proc* 61:9-13.
- Kokkoris CP. 1983. Leptomeningeal carcinomatosis: how does cancer reach the pia-arachnoid? *Cancer* 51:154-160.
- Kramer ED, Rafto S, Packer RJ, Zimmerman RA. 1991. Comparison of myelography with CT follow-up versus gadolinium MRI for subarachnoid metastatic disease in children. *Neurology* 41:46-50.
- Kun LE, Camitta BM, Mulhern RK, et al. 1984. Treatment of meningeal relapse in childhood acute lymphoblastic leukemia. I. Results of craniospinal irradiation. *J Clin Oncol* 2:359-364.
- Larson SM, Schall GL, Di Chiro G. 1981. The influence of previous lumbar puncture and pneumoencephalography on the incidence of unsuccessful radioisotope cisternography. *J Nucl Med* 12:555-557.
- Laske DW, Muraszko KM, Oldfield EH, et al. 1997. Intraventricular immunotoxin therapy for leptomeningeal neoplasia. *Neurosurgery* 41:1039-1049.
- Lim V, Sobel DF, Zyroff J. 1990. Spinal cord pial metastases: MR imaging with gadopentetate dimeglumine. *Am J Roentgenol* 155:1077-1084.
- Little JR, Dale AJ, Okazaki H. 1974. Meningeal carcinomatosis: clinical manifestations. *Arch Neurol* 30:138-143.
- Lopez JA, Nassif E, Vannicola P, et al. 1985. Central nervous system pharmacokinetics of high-dose cytosine arabinoside. *J Neurooncol* 3:119-124.
- Lyons MK, Meyer FB. 1990. Cerebrospinal fluid physiology and the management of increased intracranial pressure. *Mayo Clin Proc* 65:684-707.
- Malkin MG, Posner JB. 1987. Cerebrospinal fluid tumor markers for the diagnosis and management of leptomeningeal metastases. *Eur J Cancer Clin Oncol* 23:1-4.
- Mason WP, DeAngelis LM, Yeh SDJ. 1996. ¹¹¹Indium-DTPA cerebrospinal fluid (CSF) studies in leptomeningeal metastases (LM) predict intrathecal methotrexate (MTX) distribution and response to therapy. *Proc ASCO* 15:155.
- Mittl RL Jr, Yousem DM. 1994. Frequency of unexplained meningeal enhancement in the brain after lumbar puncture. *Am J Neuroradiol* 15:633-638.
- Moss HA, Nannis ED, Poplack DG. 1981. The effects of prophylactic treatment of the central nervous system on the intellectual functioning of children with acute lymphocytic leukemia. *Am J Med* 71:47-52.
- Murray JJ, Greco FA, Wolff SN, Hainsworth JD. 1983. Neoplastic meningitis: Marked variations of cerebrospinal fluid composition in the absence of extradural block. *Am J Med* 75:289-294.
- Newton HB, Fleisher M, Schwartz MK, Malkin MG. 1991. Glucosephosphate isomerase as a CSF marker for leptomeningeal metastasis. *Neurology* 41:395-398.
- Olson ME, Chernik NL, Posner JB. 1974. Infiltration of leptomeninges by systemic cancer: a clinical and pathologic study. *Arch Neurol* 30:122-137.
- O'Marcaigh AS, Johnson CM, Smithson WA, et al. 1996. Successful treatment of intrathecal methotrexate overdose by using ventriculolumbar perfusion and intrathecal instillation of carboxypeptidase G₂. *Mayo Clin Proc* 71:161-165.
- Packer RJ, Siegel KR, Sutton LN, Litmann P, Bruce DA, Schut L. 1985. Leptomeningeal dissemination of primary central nervous system tumors of childhood. *Ann Neurol* 18:217-221.
- Paolucci G, Rosito P. 1983. Adverse sequelae of central nervous system prophylaxis in acute lymphoblastic leukemia. In: Mastrangelo R, Poplack D, Riccardi R (eds), *Central Nervous System Leukemia*. Boston: Martinus Nijhoff Publishers, pp 105-111.
- Pasqualini T, McCalla J, Berg S, et al. 1991. Subtle primary hypothyroidism in patients treated for acute lymphoblastic leukemia. *Acta Endocrinol* 124:375-380.
- Pizer BL, Kemshead JT. 1994. The potential of targeted radiotherapy in the treatment of central nervous system leukaemia. *Leuk Lymphoma* 15:281-289.
- Pizzo P, Poplack DG, Bleyer WA. 1979. Neurotoxicities of current leukemia therapy. *Am J Pediatr Hematol Oncol* 1:127-140.
- Poplack D, Bleyer W, Horowitz M. 1980. Pharmacology of antineoplastic agents in cerebrospinal fluid. In: Wood JH (ed), *Neurobiology of Cerebrospinal Fluid*, vol 11. New York: Plenum Press, pp 561-578.
- Poplack DG, Brouwers P. 1985. Adverse sequelae of central nervous system therapy. In: Nesbit ME (ed), *Clinics in Oncology*. Philadelphia: WB Saunders, pp 263-285.
- Posner JB, Chernik NL. 1978. Intracranial metastases from systemic cancer. *Adv Neurol* 19:579-592.
- Ram Z, Walbridge S, Oshiro EM, et al. 1994. Intrathecal gene

- therapy for malignant leptomeningeal neoplasia. *Cancer Res* 54:2141-2145.
- Recht LD. 1991. Neurologic complications of systemic lymphoma. *Neurol Clin* 9:1001-1015.
- Rogers LR, Duchesneau PM, Nunez C, et al. 1992. Comparison of cisternal and lumbar CSF examination in leptomeningeal metastasis. *Neurology* 42:1239-1241.
- Rosen ST, Aisner J, Makuch RW, et al. 1982. Carcinomatous leptomeningitis in small cell lung cancer: a clinicopathologic review of the National Cancer Institute experience. *Medicine* 61:45-53.
- Rosenfeld MR, Bergman I, Schramm L, Griffin JA, Kaplitt MG, Meneses PI. 1997. Adeno-associated viral vector gene transfer into leptomeningeal xenografts. *J Neurooncol* 34:139-144.
- Schipper HI, Bardosi A, Jacobi C, Felgenhauer K. 1988. Meningeal carcinomatosis: origin of local IgG production in the CSF. *Neurology* 38:413-416.
- Schold SC, Wasserstrom WR, Fleisher M, Schwartz MK, Posner JB. 1980. Cerebrospinal fluid biochemical markers of central nervous system metastases. *Ann Neurol* 8:597-604.
- Serabe BM, Murry DJ, Dauser R, et al. 1999. Plasma and CSF pharmacokinetics of ganciclovir in nonhuman primates. *Cancer Chemother Pharmacol* 43:415-418.
- Shapiro WR, Posner JB, Ushio Y, Chemik NL, Young DF. 1977. Treatment of meningeal neoplasms. *Cancer Treat Rep* 61:733-743.
- Shapiro WR, Young DF, Mehta BM. 1975. Methotrexate: distribution in cerebrospinal fluid after intravenous, ventricular and lumbar injections. *N Engl J Med* 293:161-166.
- Strong JM, Collins JM, Lester C, Poplack DG. 1986. Pharmacokinetics of intraventricular and intravenous N,N',N''-triethylenethiophosphoramide (thiotepa) in rhesus monkeys and humans. *Cancer Res* 46:6101-6104.
- Sze G, Abramson A, Krol G, et al. 1988. Gadolinium-DTPA in evaluation of intradural extramedullary spinal disease. *Am J Roentgenol* 150:911-921.
- Theodore WH, Gendelman S. 1981. Meningeal carcinomatosis. *Arch Neurol* 38:696-699.
- Twijnstra A, Ongerboer de Visser BW, van Zanten AP, Hart AA, Nooyen WF. 1989. Serial lumbar and ventricular cerebrospinal fluid biochemical marker measurements in patients with leptomeningeal metastases from solid and hematologic tumors. *J Neurooncol* 7:57-63.
- Van Oostenbrugge RJ, Hopman AHN, Lenders MH, et al. 1997. Detection of malignant cells in cerebrospinal fluid using fluorescence in situ hybridization. *J Neuropathol Exp Neurol* 56:743-748.
- Van Oostenbrugge RJ, Twijnstra A. 1999. Presenting features and value of diagnostic procedures in leptomeningeal metastases. *Neurology* 53:382-385.
- Voorhess ML, Brecher ML, Glicksman AS, et al. 1986. Hypothalamic-pituitary function of children with acute lymphocytic leukemia after three forms of central nervous system prophylaxis. A retrospective study. *Cancer* 57:1287-1291.
- Walker RW. 1991. Neurologic complications of systemic cancer: neurologic complications of leukemia. *Neurol Clin* 9:989-999.
- Walter AW, Hancock ML, Pui CH, et al. 1998. Secondary brain tumors in children treated for acute lymphoblastic leukemia at St Jude Children's Research Hospital. *J Clin Oncol* 16:3761-3767.
- Wasserstrom WR, Glass JP, Posner JB. 1982. Diagnosis and treatment of leptomeningeal metastases from solid tumors: experience with 90 patients. *Cancer* 49:759-772.
- Wolff L, Zigelboim J, Gale RP. 1979. Paraplegia following intrathecal cytosine arabinoside. *Cancer* 43:83-85.
- Yung WA, Horten BC, Shapiro WR. 1980. Meningeal gliomatosis: a review of 12 cases. *Ann Neurol* 8:605-608.
- Zamboni WC, Gajjar AJ, Mandrell TD, et al. 1998. A four-hour topotecan infusion achieves cytotoxic exposure throughout the neuraxis in the nonhuman primate model: implications for treatment of children with metastatic medulloblastoma. *Clin Cancer Res* 4:2537-2544.
- Zimm S, Collins JM, Miser J, Chatterji D, Poplack DG. 1984. Cytosine arabinoside cerebrospinal fluid kinetics. *Clin Pharmacol Ther* 35:826-830.
- Zovickian J, Youle RJ. 1988. Efficacy of intrathecal immunotoxin therapy in an animal model of leptomeningeal neoplasia. *J Neurosurg* 68:767-774.

